



Uncovering the hidden cause

Dr. Rasha Mousa
MD ,FRCS
MIOR

Case 1

- 63 y
- Cataract N3
- Systemic free except for hypertension

Postoperative

- Regular postoperative treatment was received for 2 weeks
- Pt was very satisfied

what happened after that ?

Postoperative

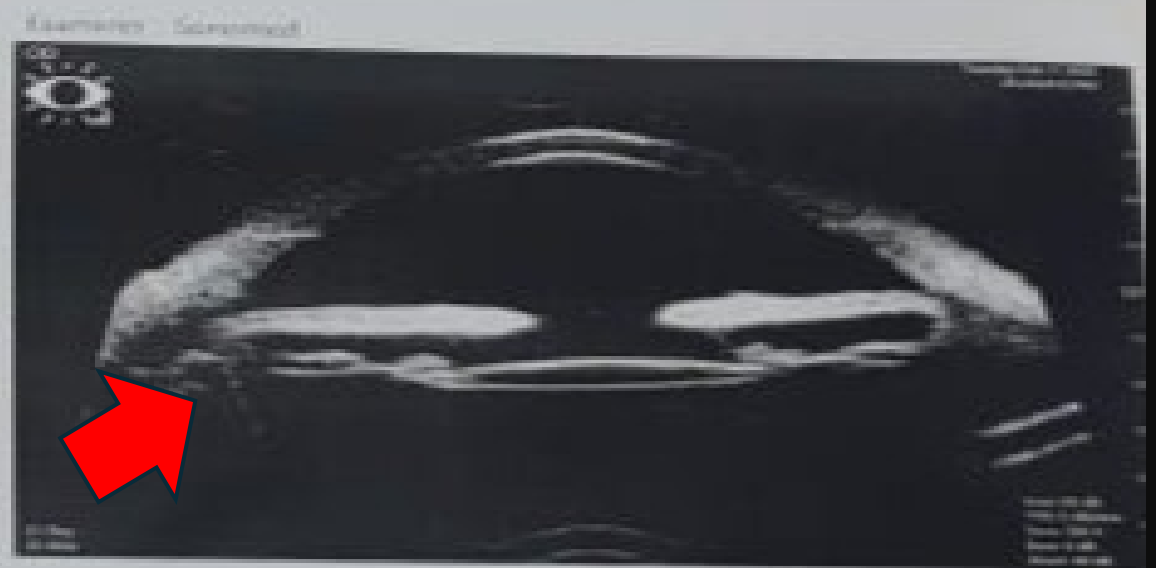
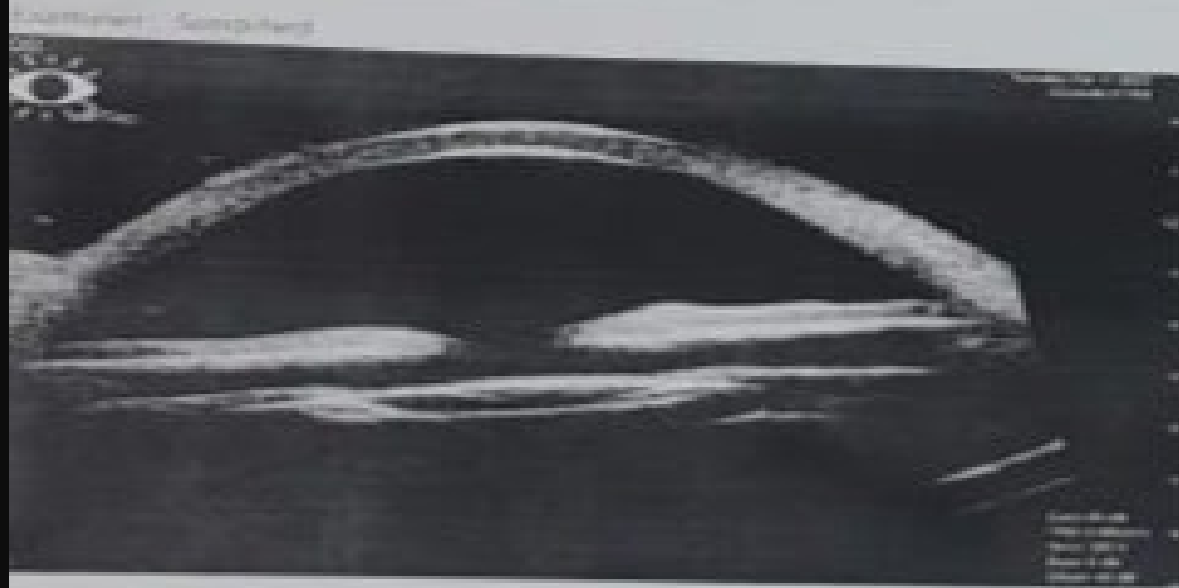
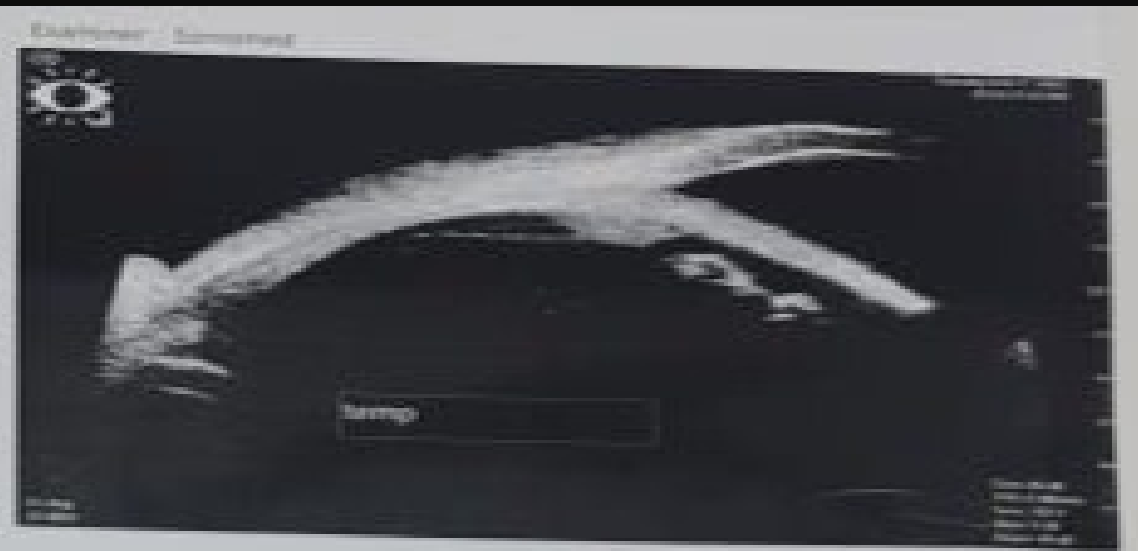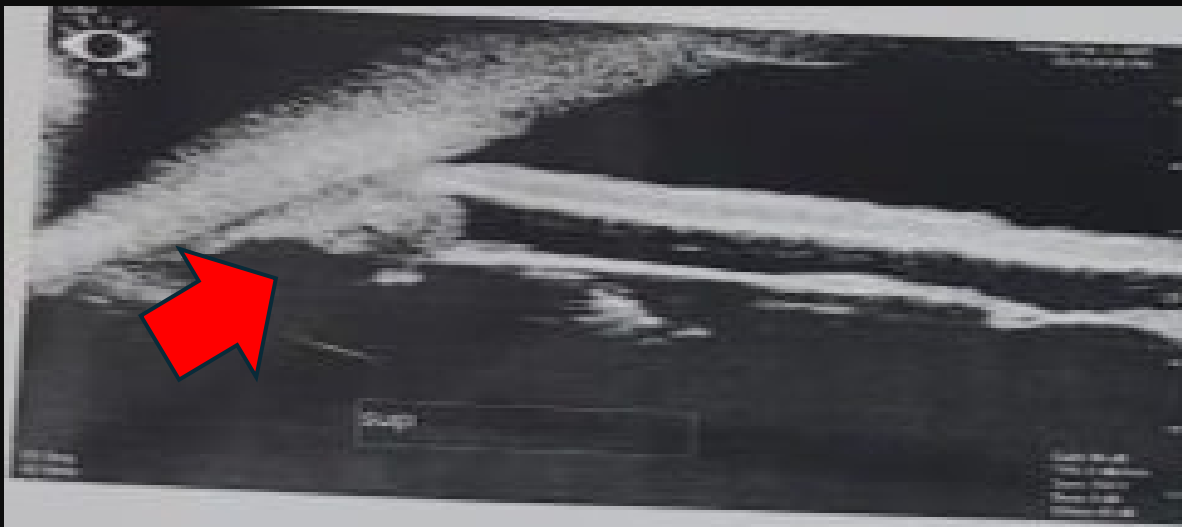- After stopping the treatment
 - Photophobia
 - Discomfort
 - Circumcorneal injection
 - AC shows +2 cells

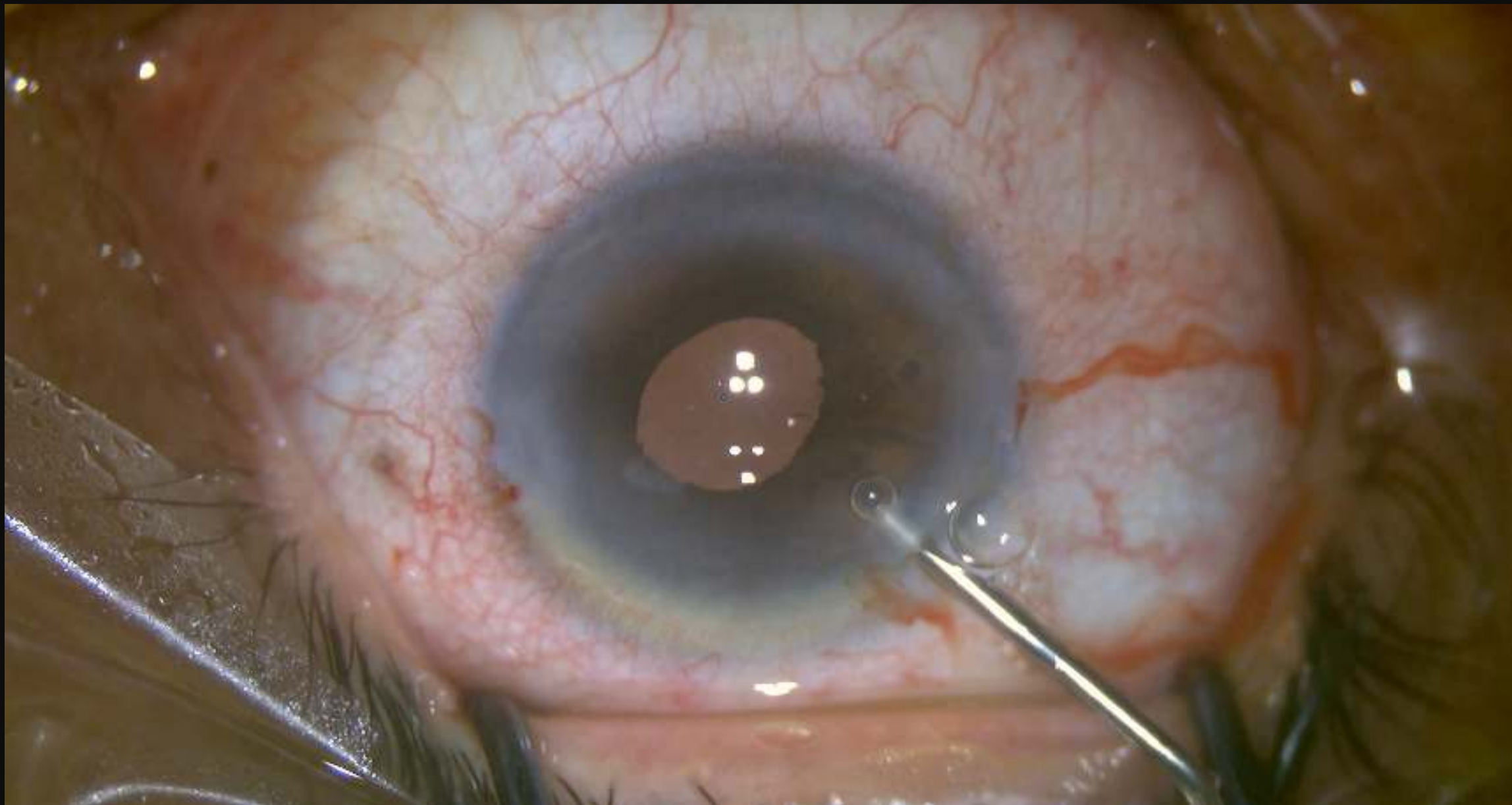
Postoperative

- We return to steroid and the symptoms improves
- But after tapering of steroid the symptoms recures
- This continues for three months
- Pt is immunologically free



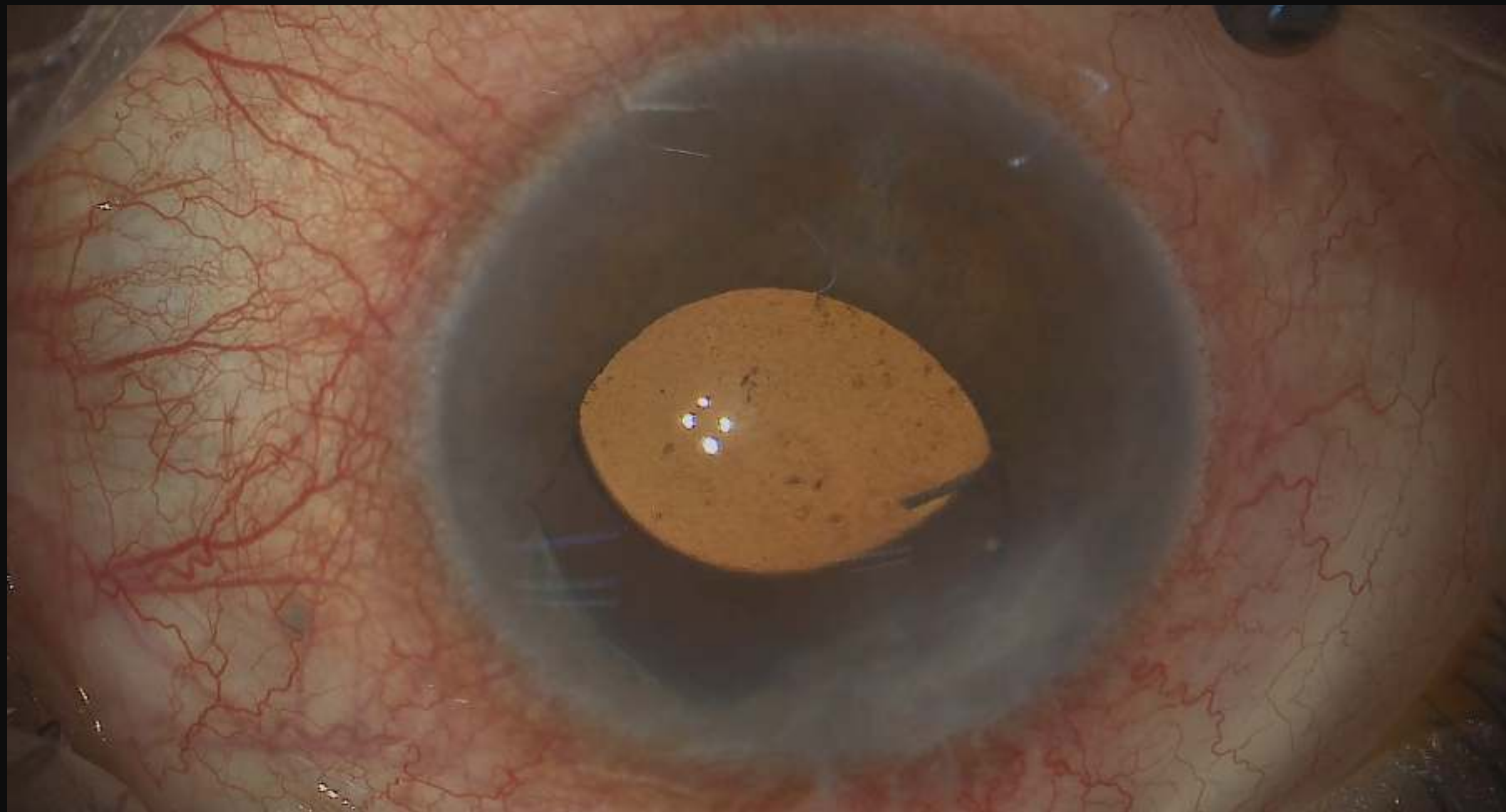
What is the possible cause ?





Case 2

- 65y old pt underwent cataract surgery which was complicated with PCR
- 3-piece IOL scleral fixated with Yamanee technique
- Postoperative the pt has very high astigmatism and vision is not corrected



Postoperative

REF. DATA

VD: 12.00

CYL: (-)

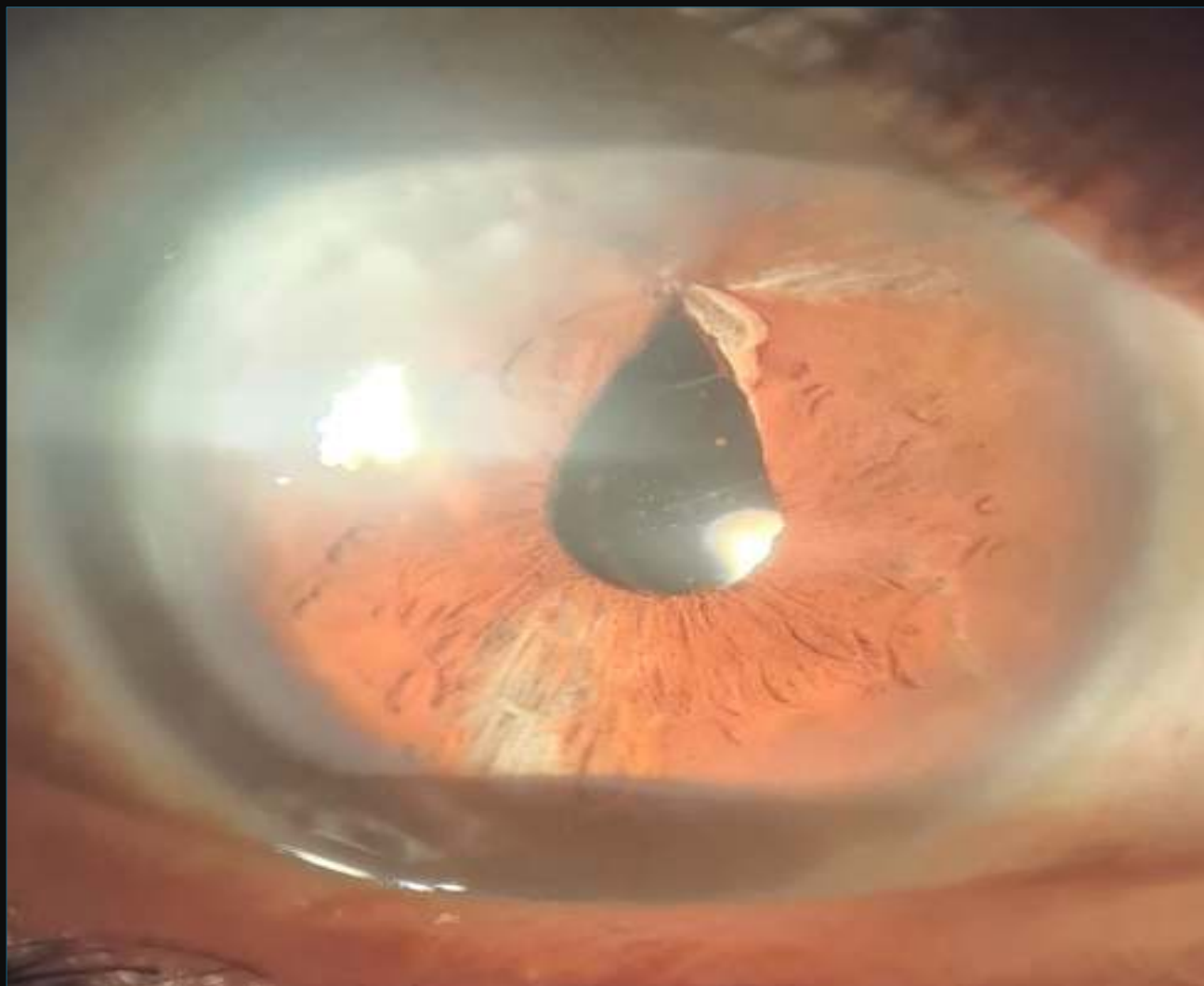
<R>	S	C	A
-	0.25	- 4.50	100
-	0.00	- 5.00	100

S. E. - 2.50

<L>	S	C	A
-	1.25	- 3.50	65
-	0.00	- 3.75	65

S. E. - 2.00

PD: 62.5



Take home message

- Always respect the pt complain
- Always suspect hidden small fragments under the iris in cases of persistent ocular inflammation after phaco .
- Simple procedures may solve big problems .

Thank
you

