

Strabismus Reoperations

Dr Abubaker Affan

Dr Hisham Khattab

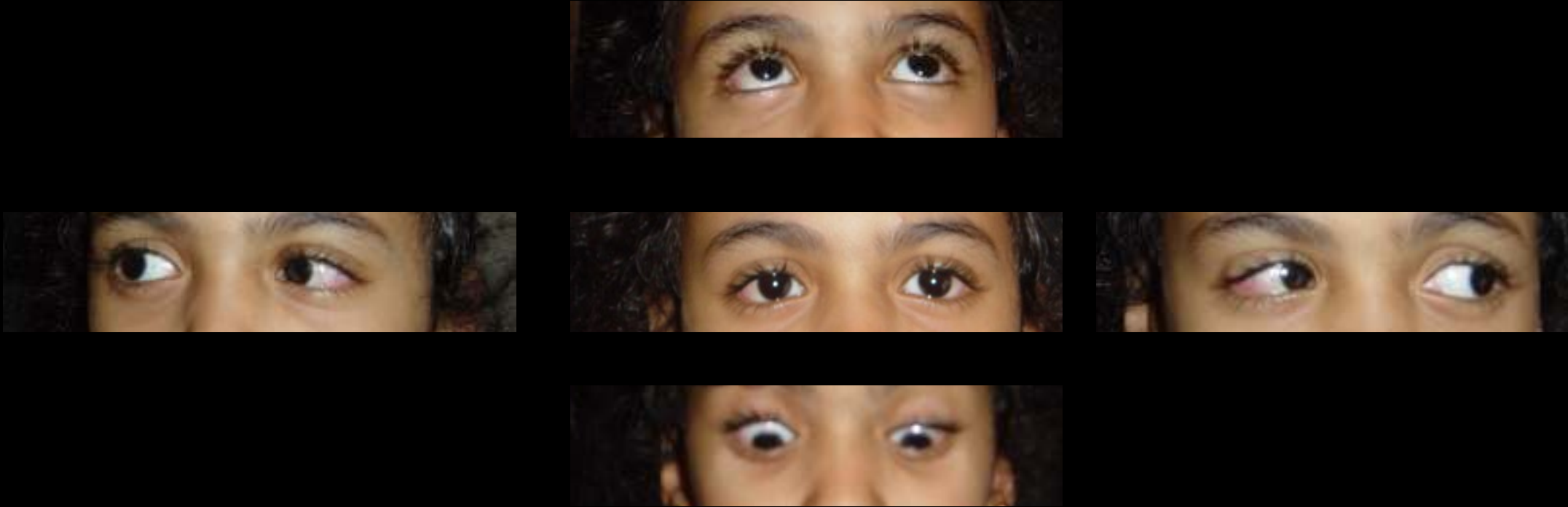
Dr Lobna Khazbak

Dr Ramesh Kekunnaya

Moderator: Dr Amr
Elkamshoushy

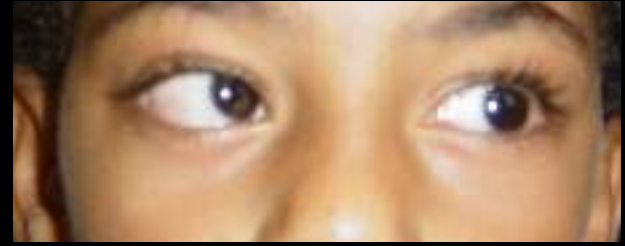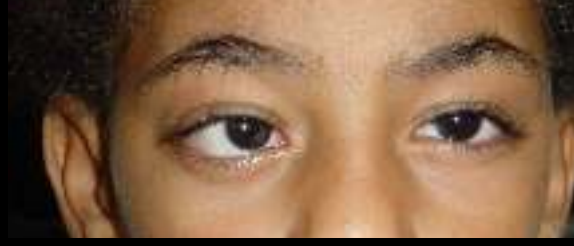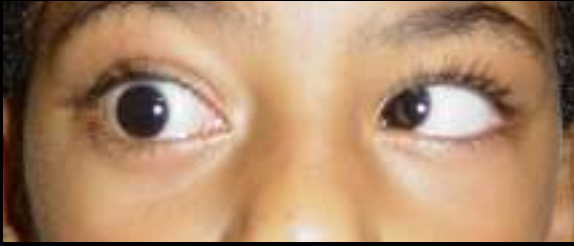What is your preoperative counselling regarding reoperation?

- How likely?
- Different conditions
- More than one reop?
- How soon to reop



Did Bil LR recession 6 mm 2 months ago

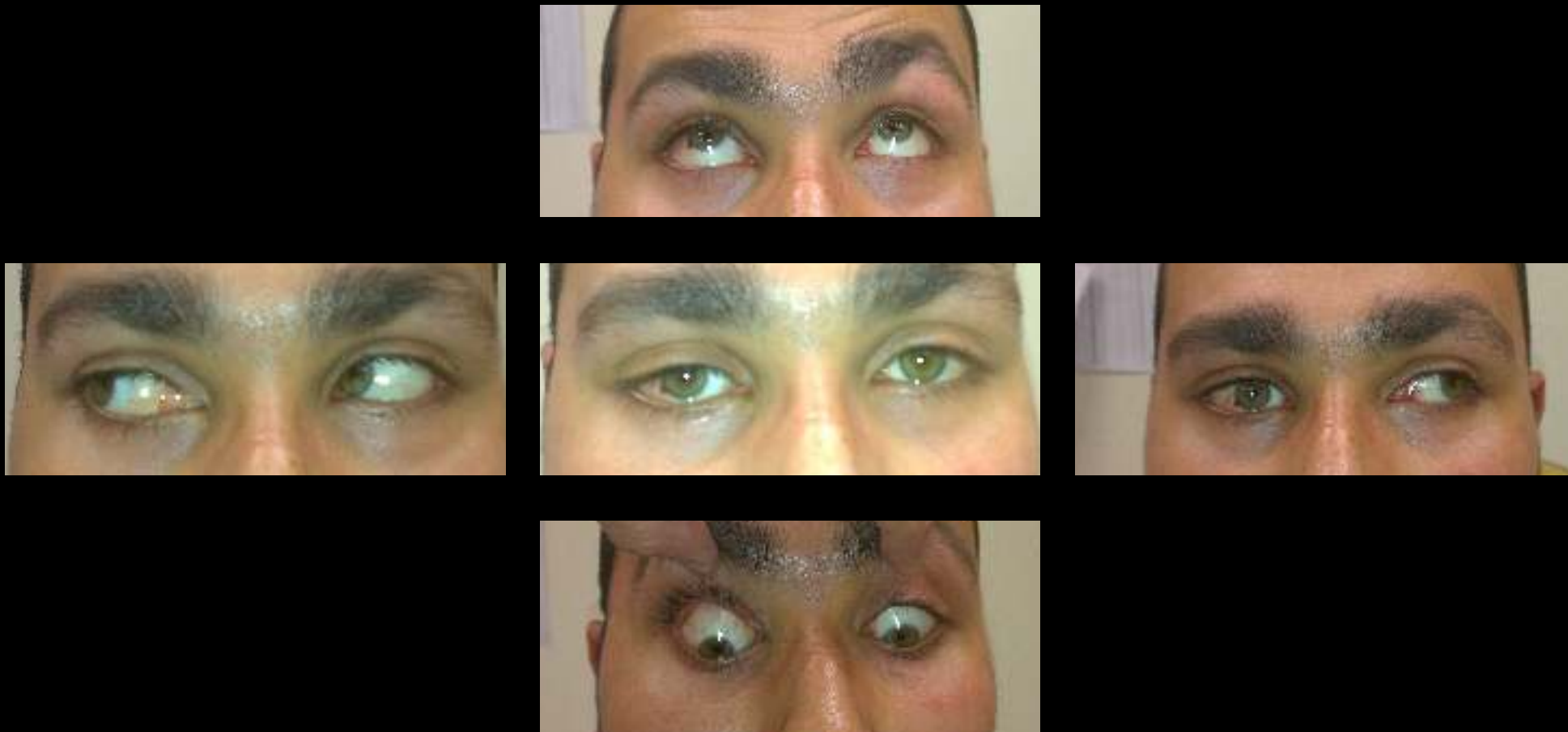- Now she has ET 8 prism diopters that has been stable for a month
- Angle is equal in all directions with no limitation



Did Bil LR recession 6 mm 2 months ago

→ Now she has ET 20 prism diopters that has been stable for a month

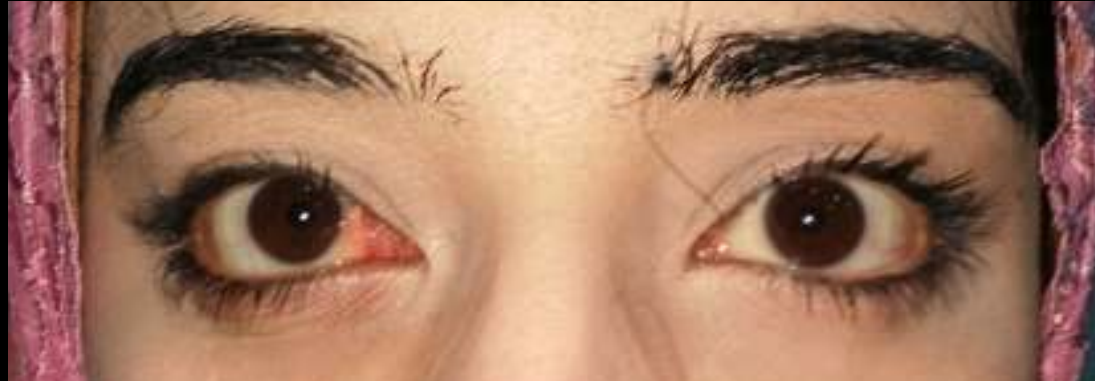→ There is limited abduction -3 OD and -2 OS



A case of esotropia 35 PD was planned for Bil MR recession 6 mm

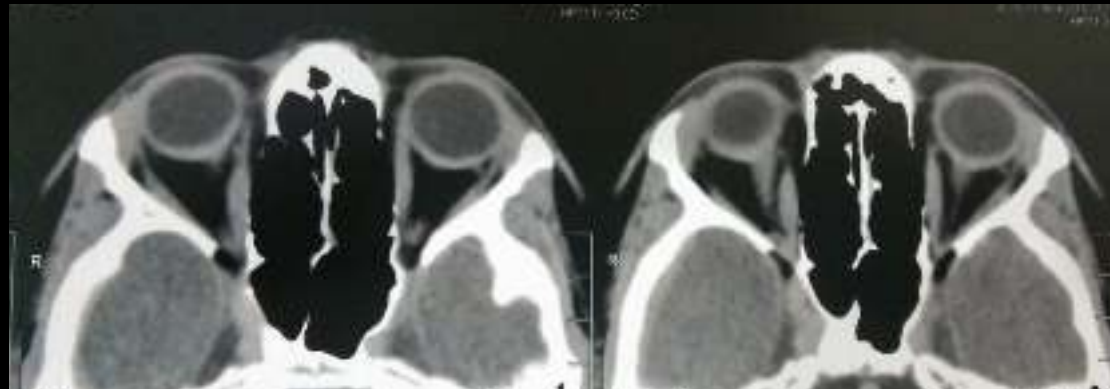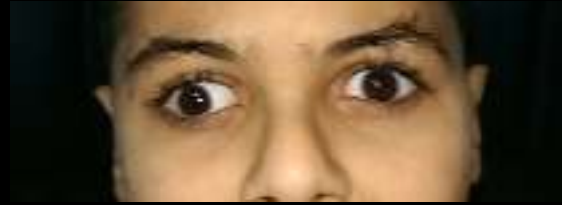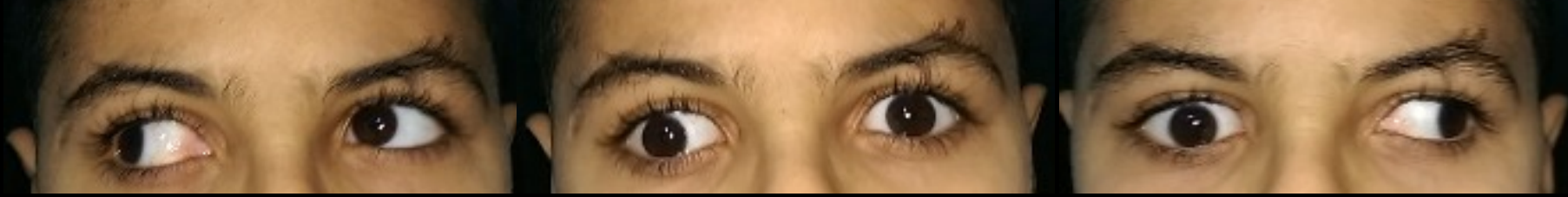Surgeon mistakenly did a Right MR resection 6 mm, realizing the mistake intra-op, the Rt MR was placed 10 mm behind insertion

This is the picture 6 weeks post op

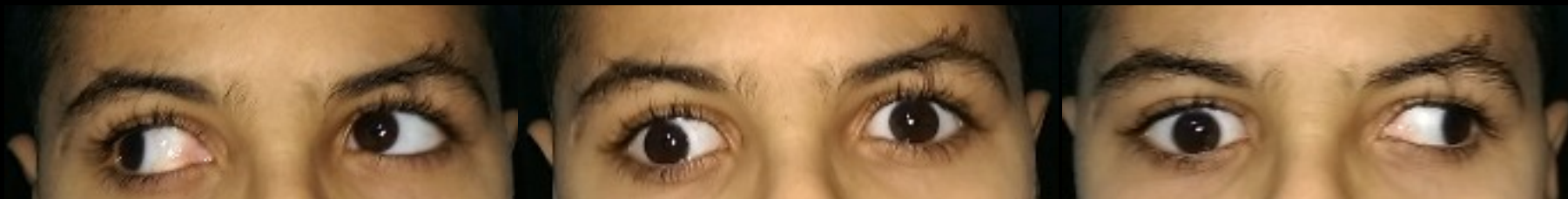

Ugly scar after right MR
advancement

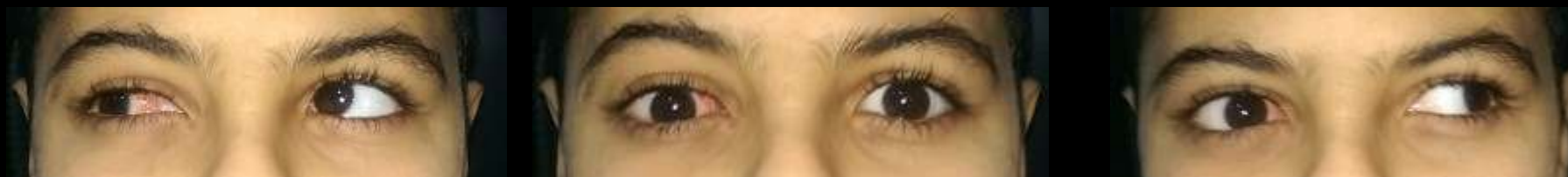History of strabismus surgery 2 years ago



Pre-operative



After transposition + resection + augmentation

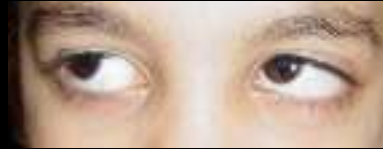

Bilateral IO overaction after Bil MR recession

IOOA
+1



IOOA
+2



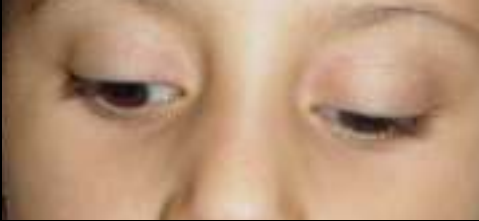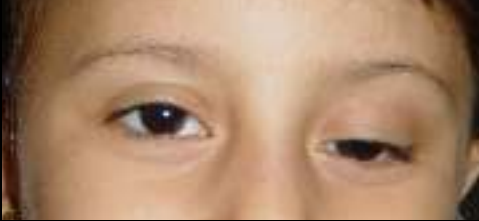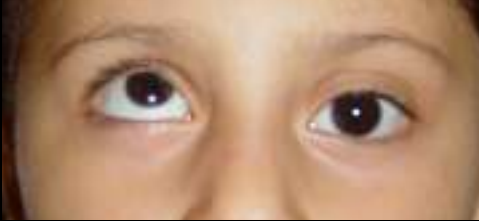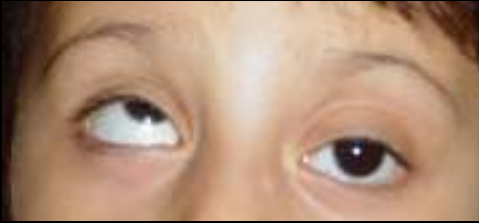IOOA
+3



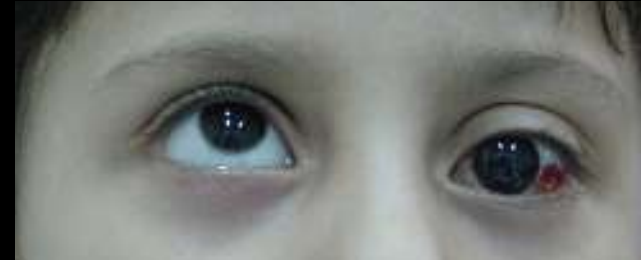IOOA
+4



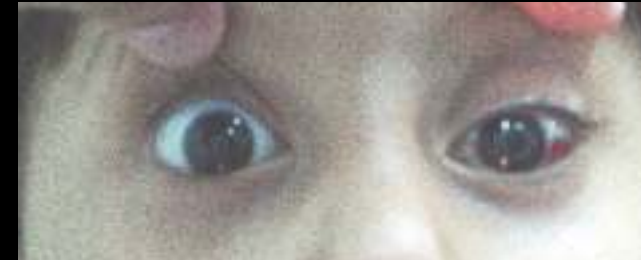Left MED



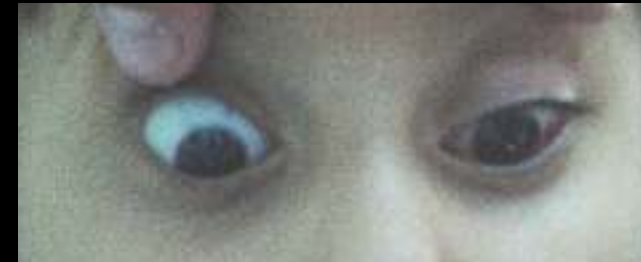After left IR recession



Right Hypotropia
30 PD

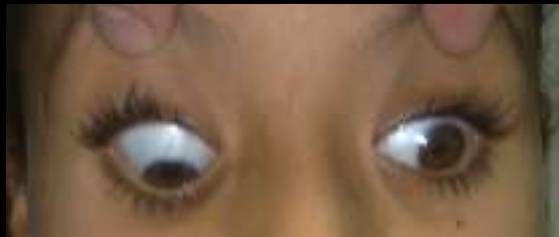
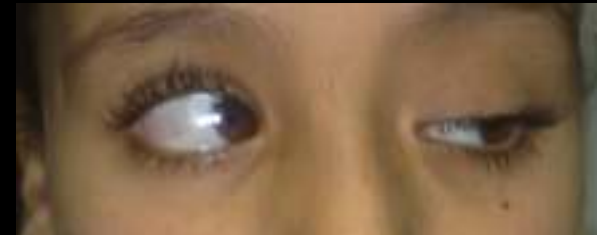
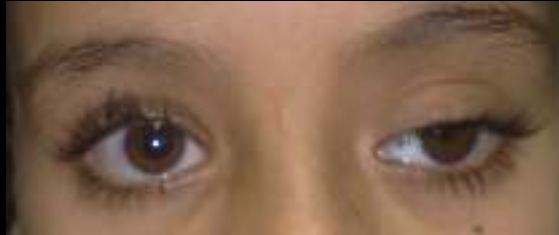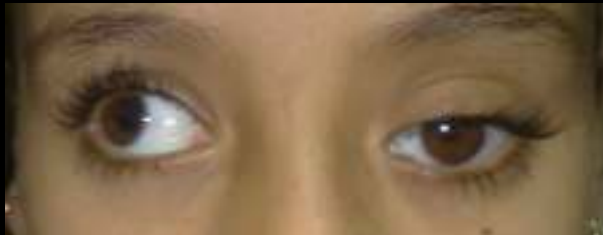No Hypertropia



Left Hypertropia
15 PD

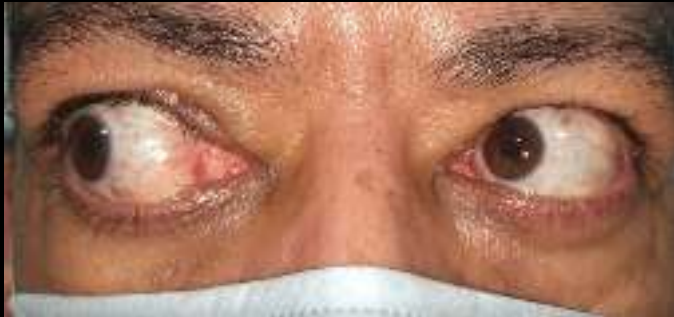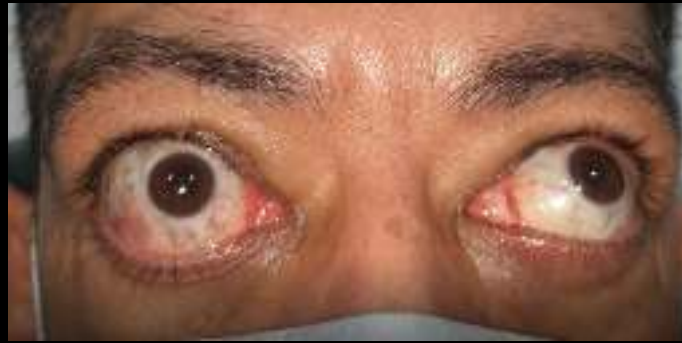Third Nerve Palsy



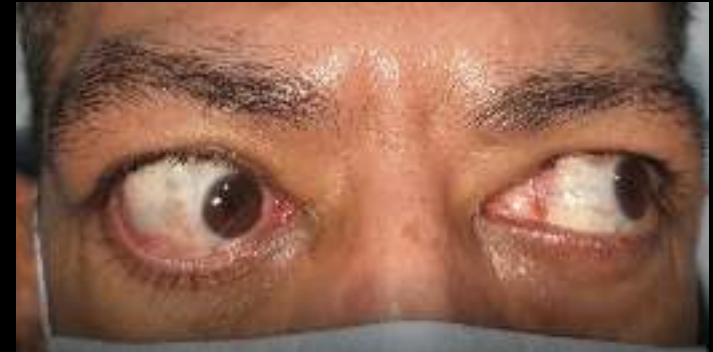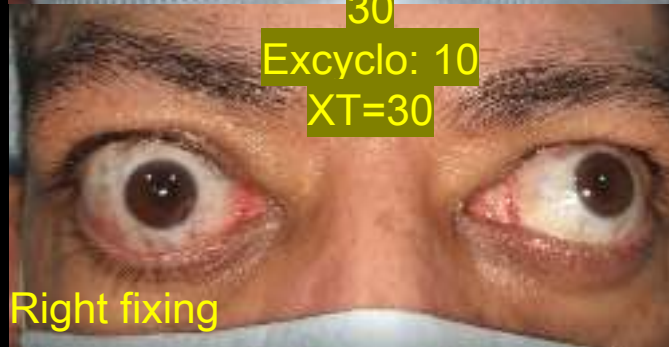
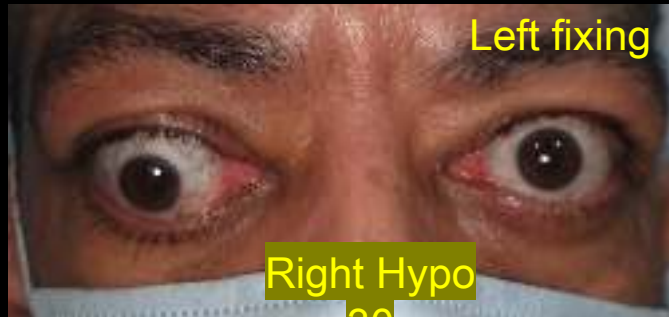
Right third n palsy
Underwent left LR recession and MR resection

- 58 yo, TED.
- Right hypo 60, swollen right IR on CT.
- Did Right IR recession 6 and left SR recession 7

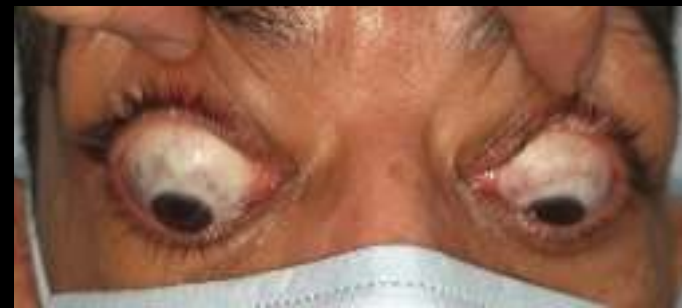S/P: Right IR rec 6 and left SR
rec 7

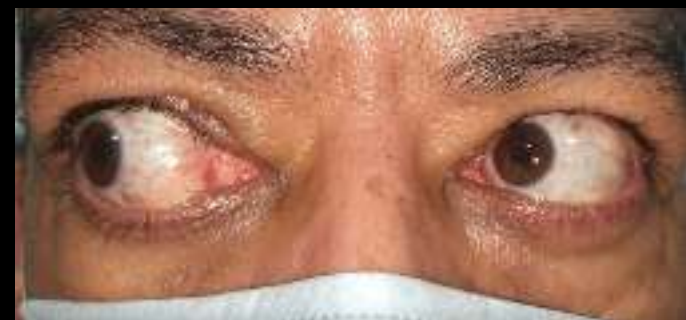

Right Hypo
14

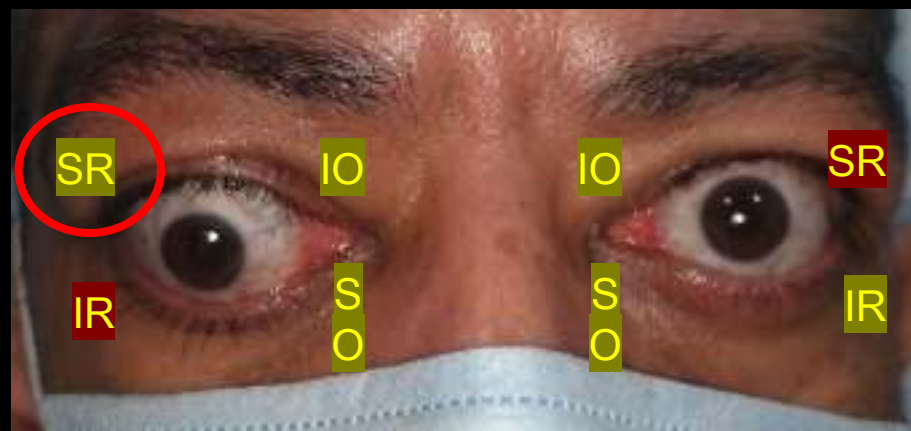

Right Hypo
30

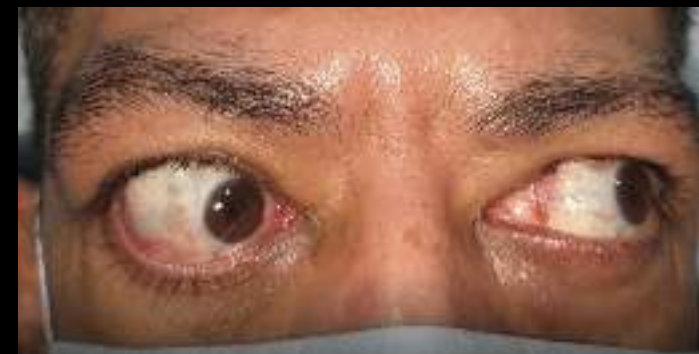



Right Hypo
14



Right Hypo 30
Excyclotorsion
10



Right Hypo
30


When can you do resections in
TED?



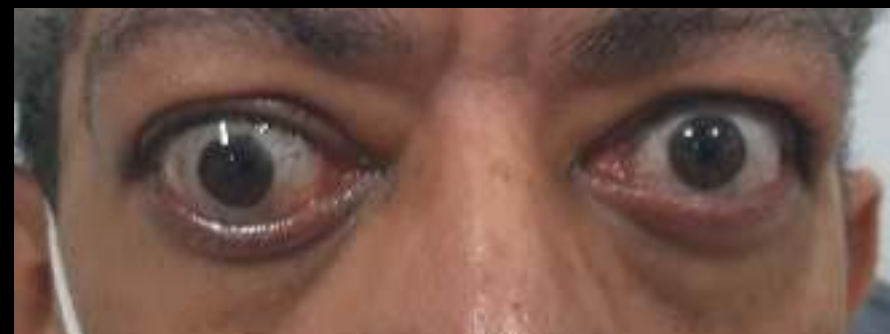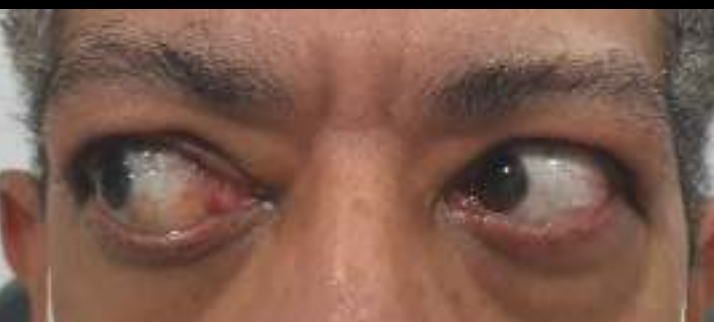Right Hypo
14



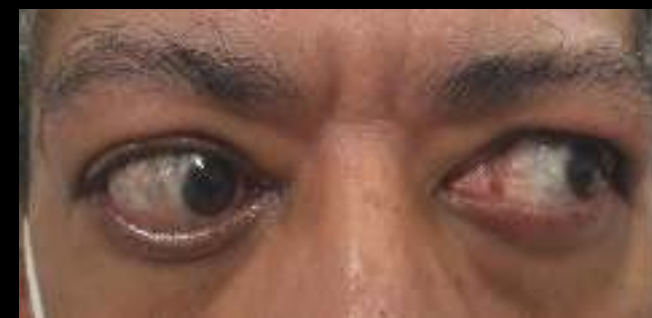Right Hypo 30
Excyclotorsion
10



Right Hypo
30



Right Hypo 14
Excyclotorsion 3



Thank You