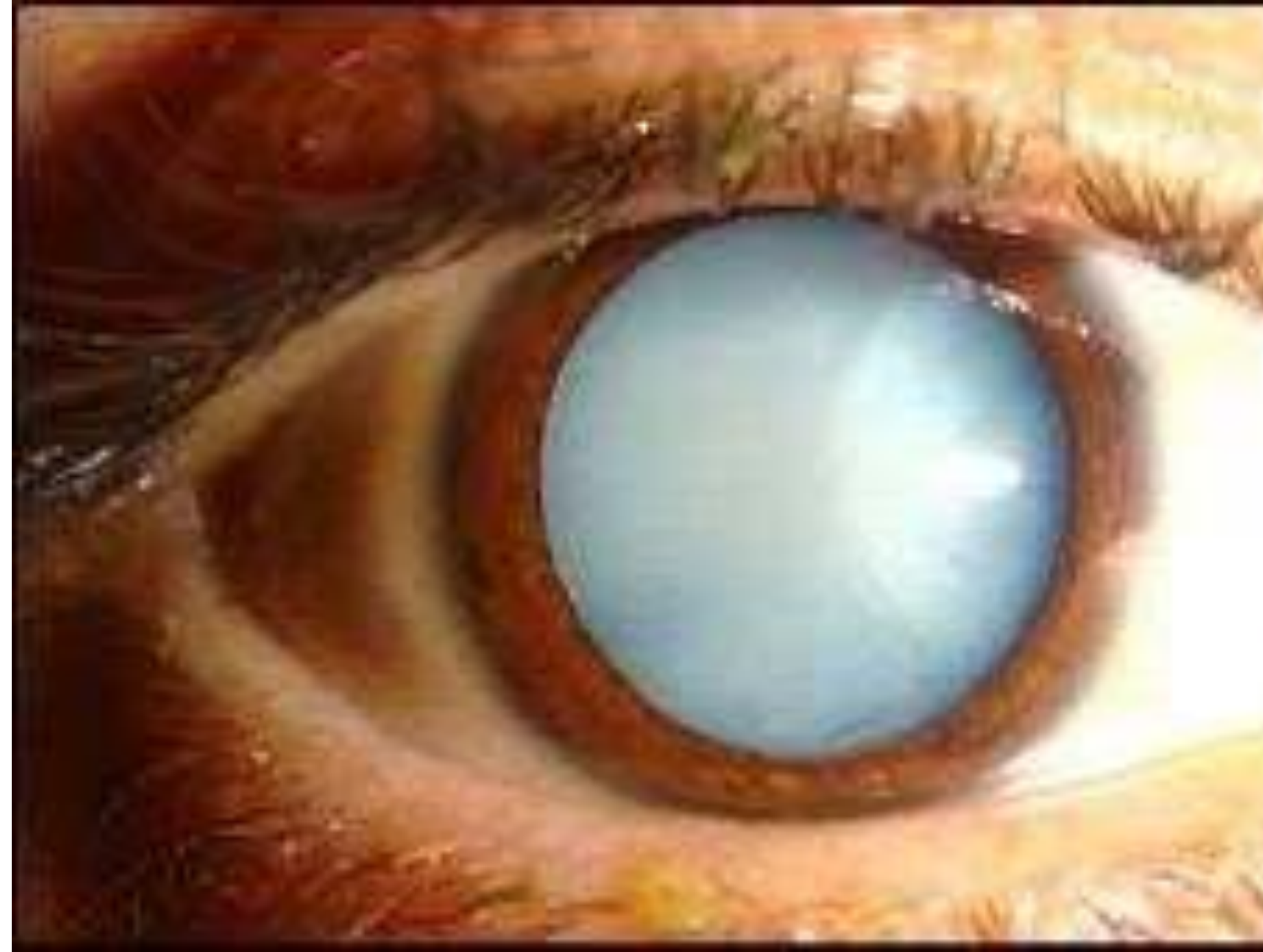



Capsulorhexis in White Cataract

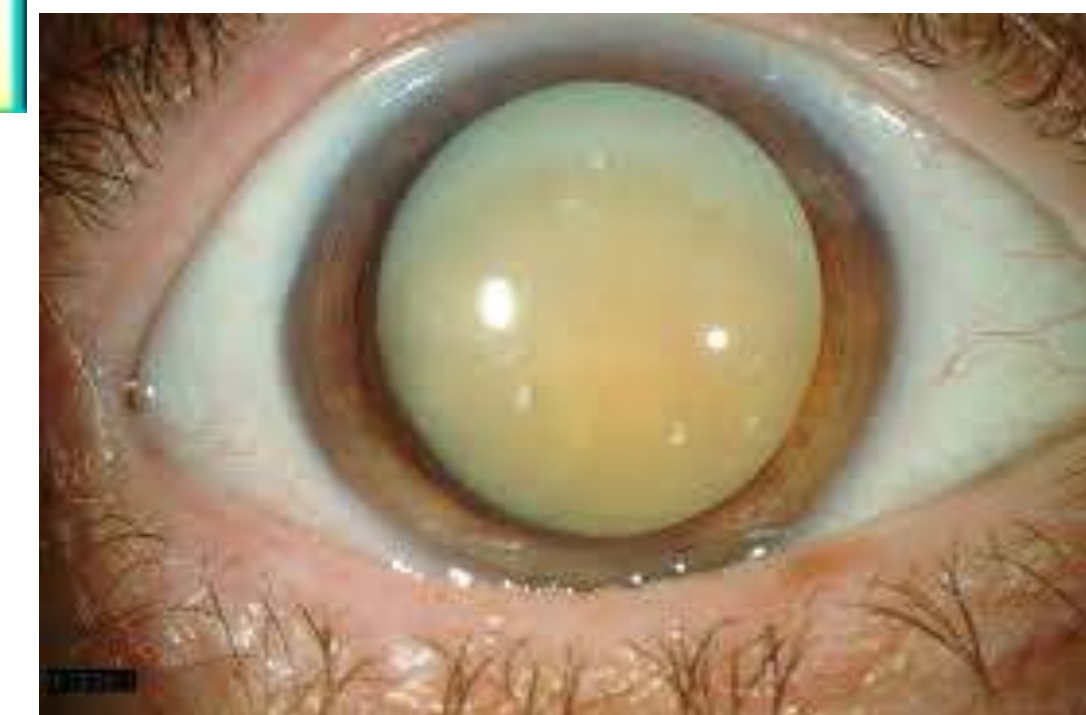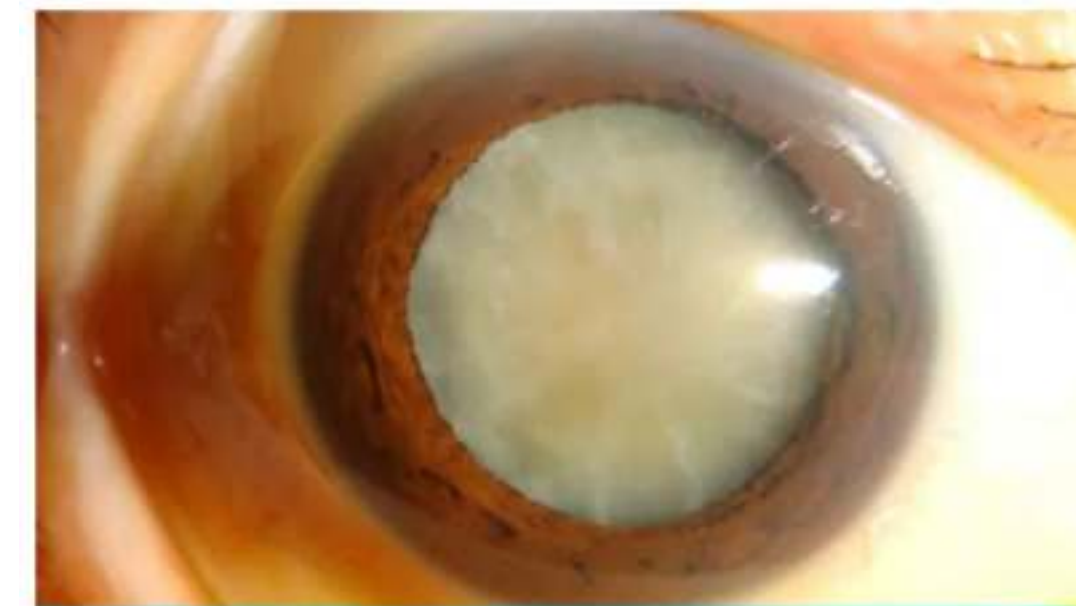
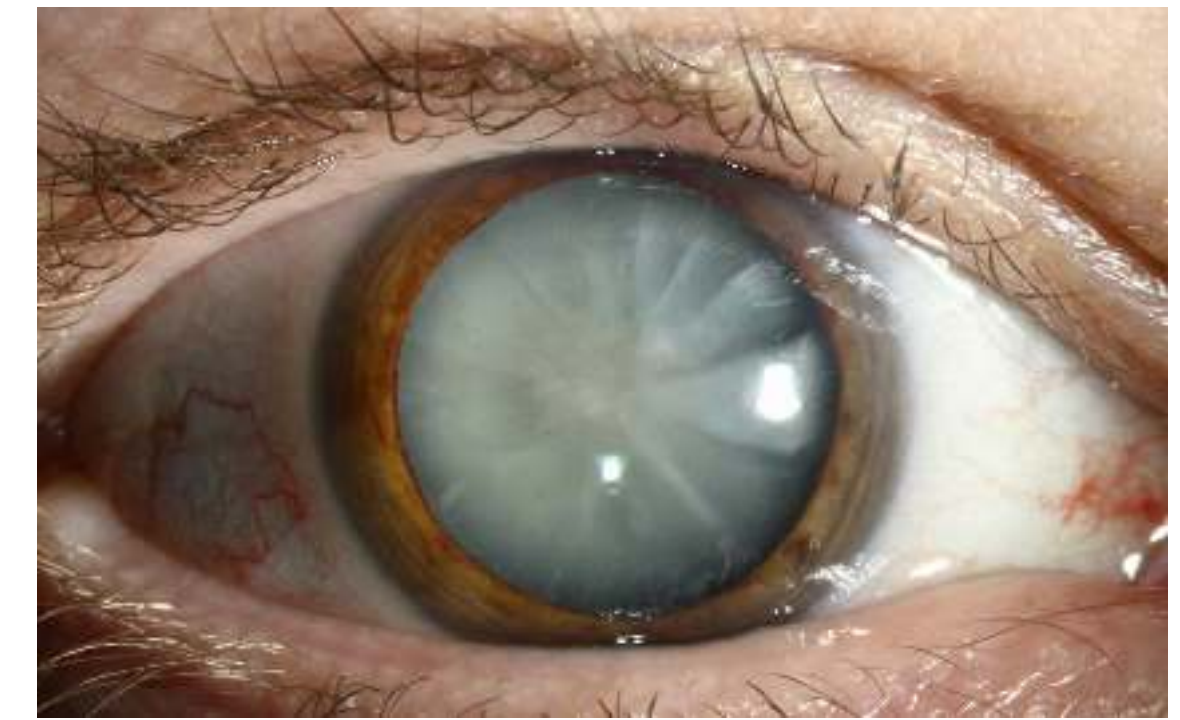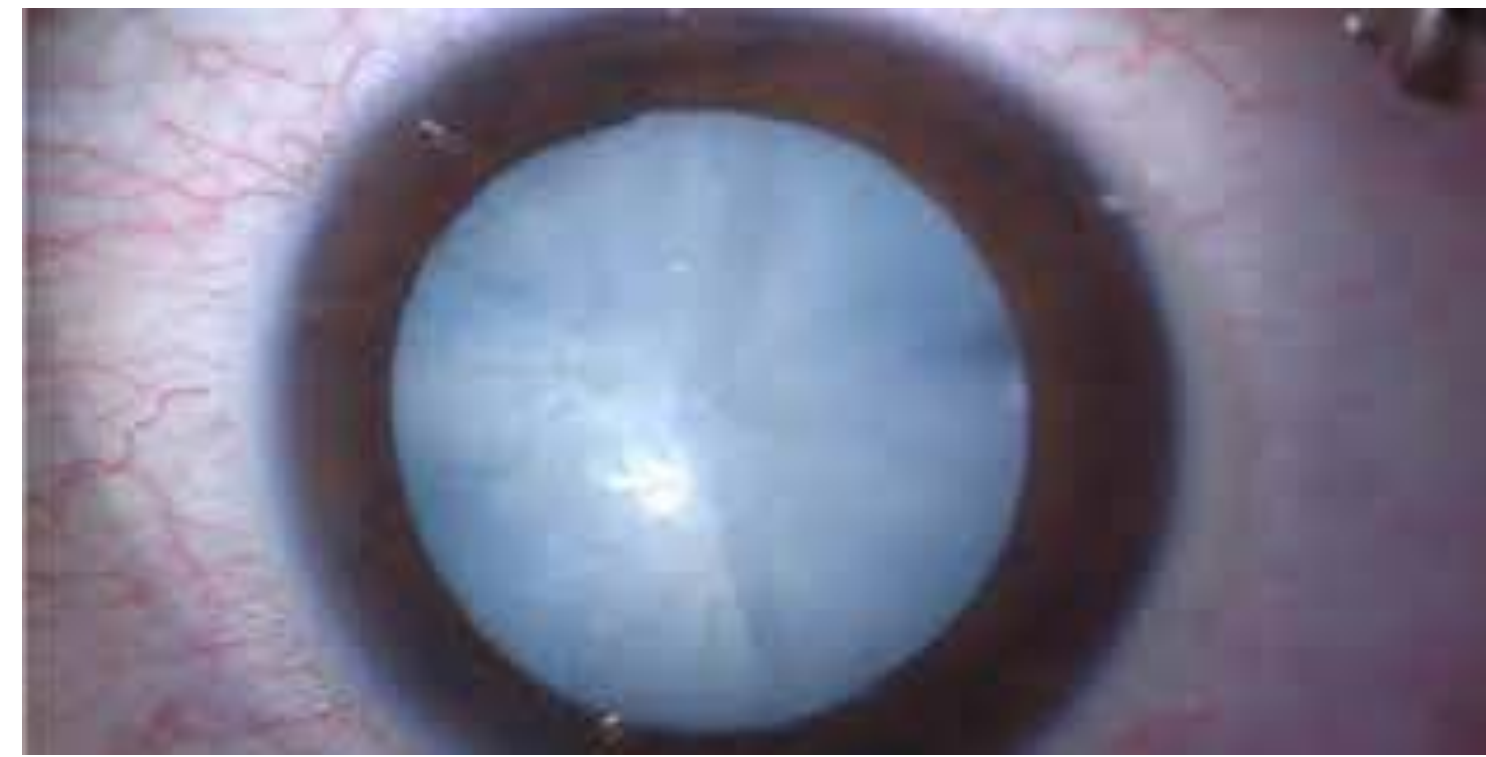Mohammed Ezzeldawla , MD
Assistant professor of ophthalmology
Sohag university

Definition

- White cataract is a severe form of lens opacity in the eye where the lens has become completely opaque and often appears milky or white

Types :

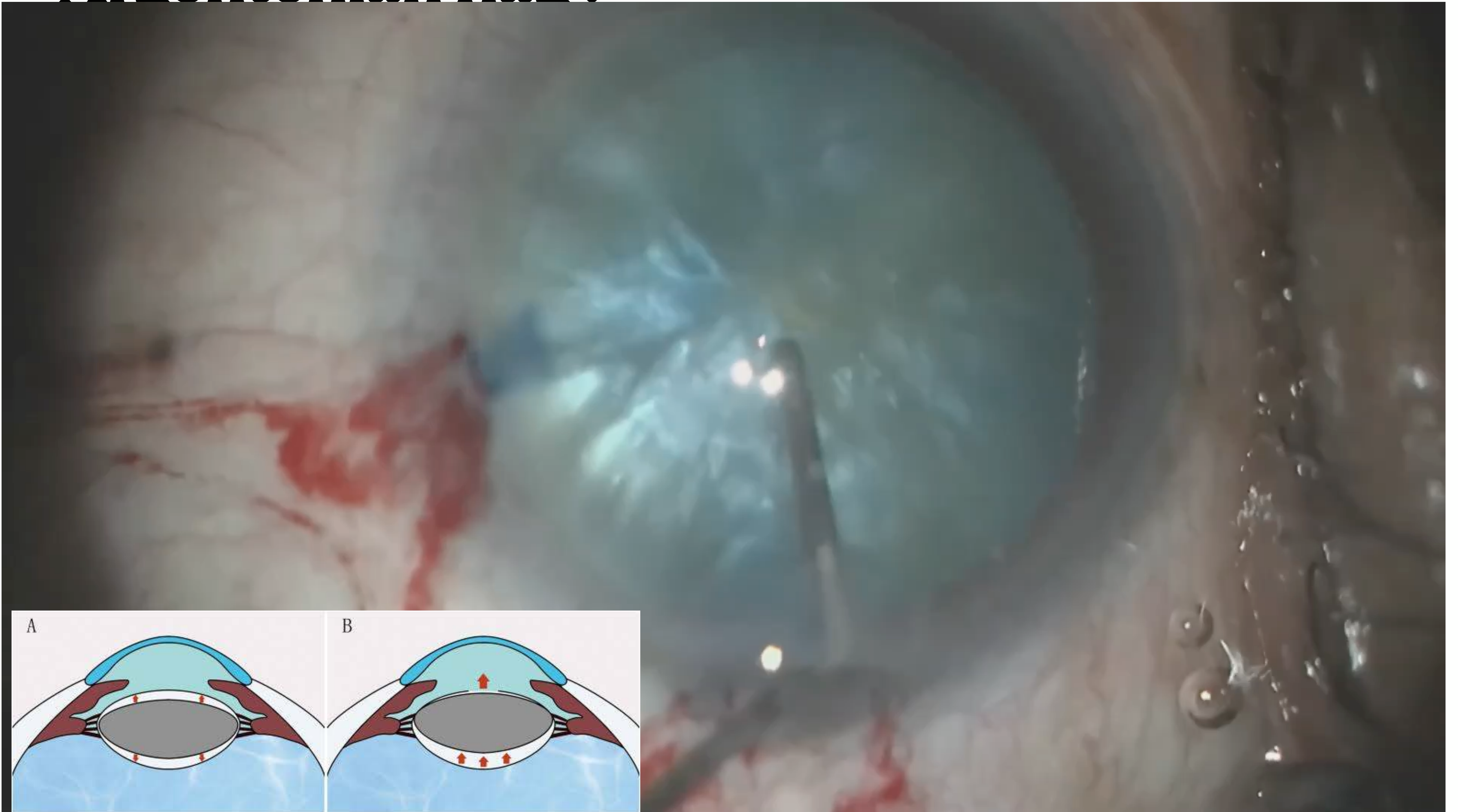
- White intumescent
 - White cortical
 - White hard
 - Morgagnian



Challenges

- Poor red reflex
- Increased intracapsular pressure
- Possibility of capsule runout

Argentinian flag!



**To Be
Or
Not To Be**

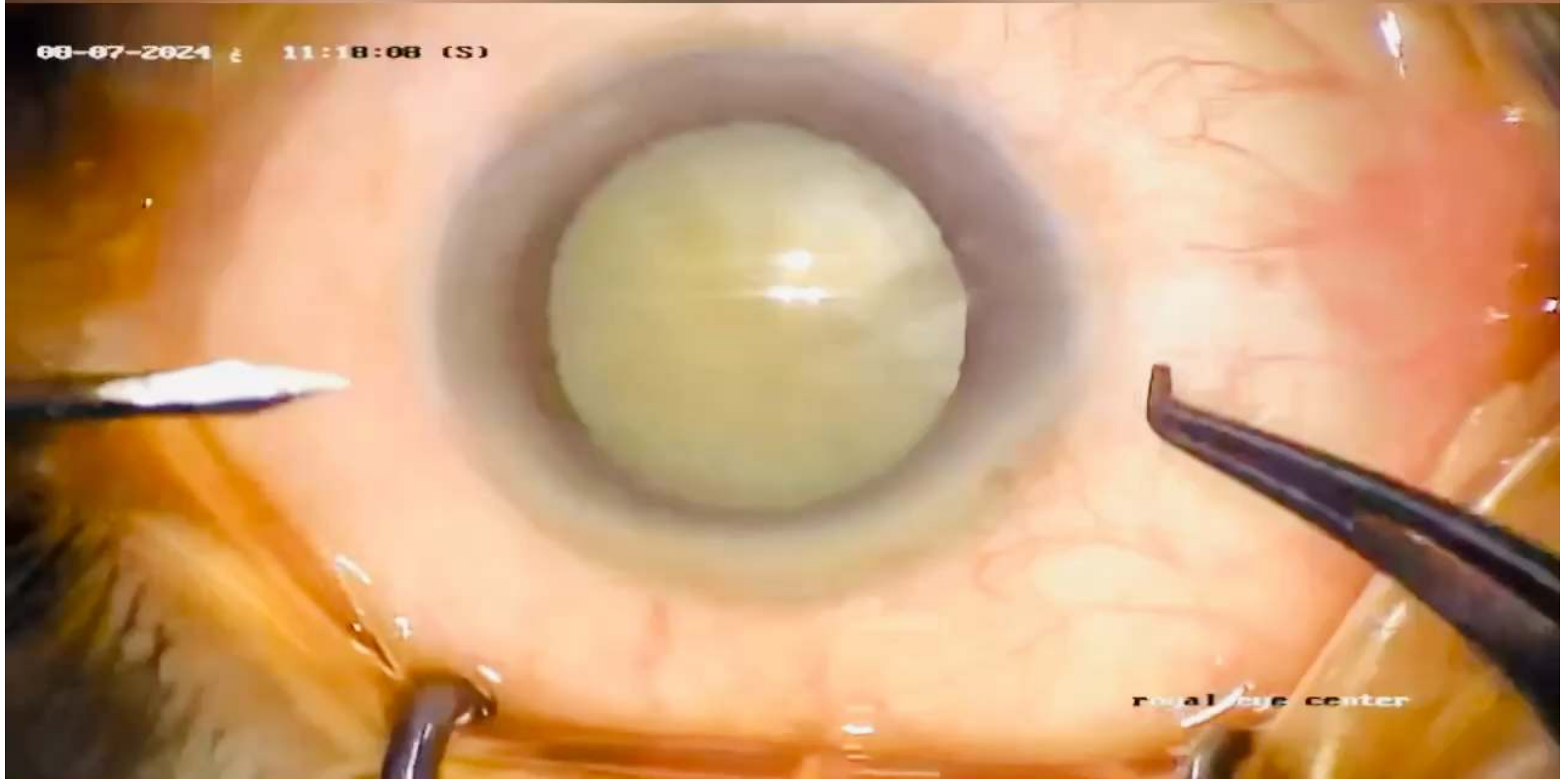
by
**William
Shakespeare**



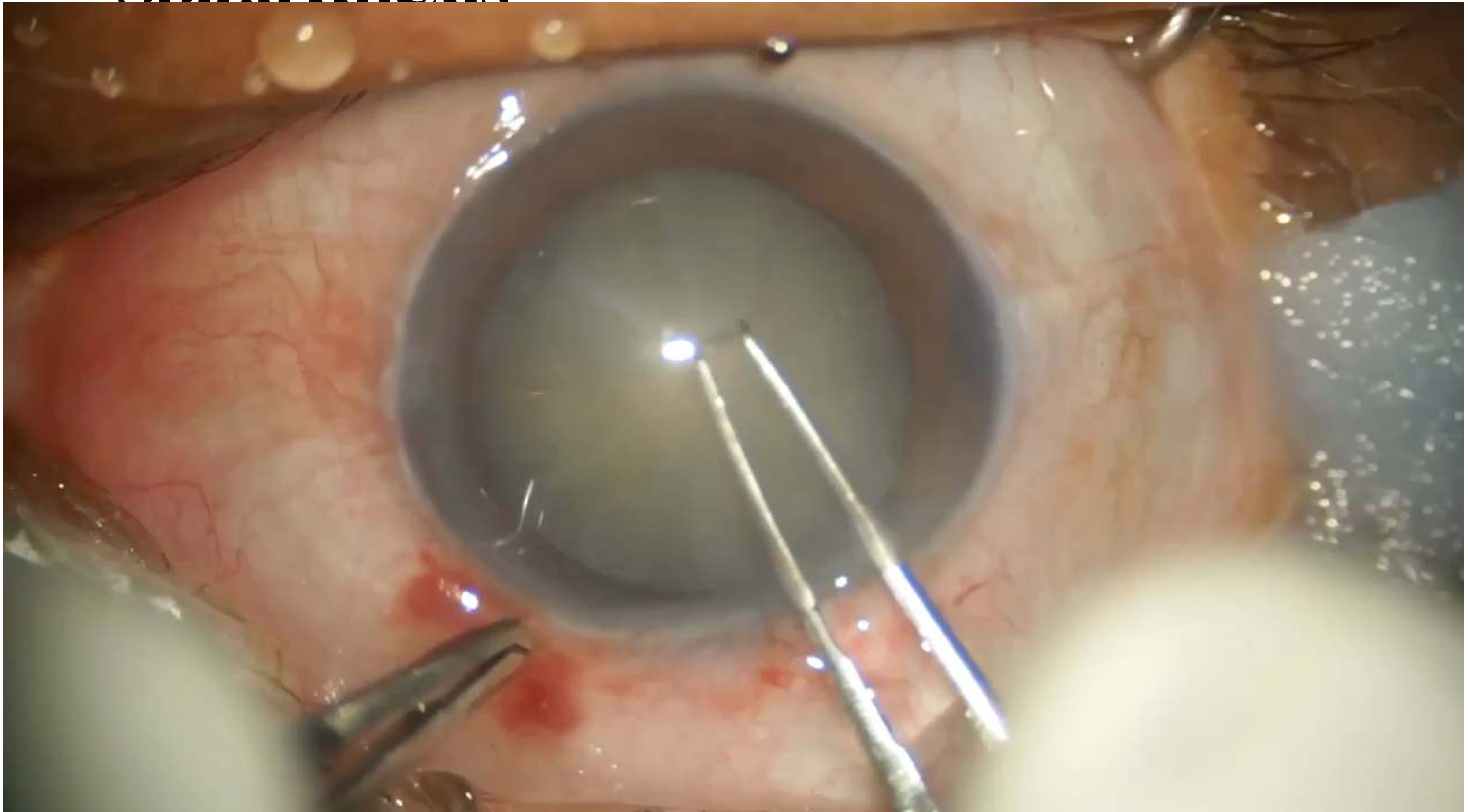
Management

- Needle aspiration
- Spiral Rhexis
- Double Rhexis
- Femtosecond Laser Assisted Cataract Surgery (FLACS)

Needle aspiration




Spiral Rhexis



Double Rhexis

DR.MOHAMED EZZ ELDAWLA

ELACS



Take home message

- Rhexis in white cataract is a crucial step
- Thoroughly pre surgical evaluation is a must
- Always refine your skills
- Use the technique you are familiar with
- You need a lot of skills and a lot of Luck !

THANK you