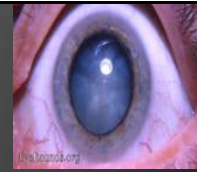



Basic Phaco Course



Coordinator:

Ahmed Ghoneim,MD (Tanta)

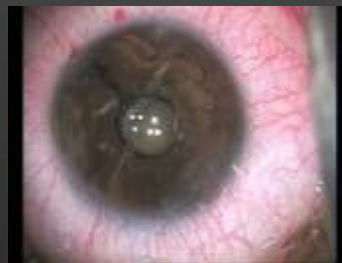Instructors:

Amr Elsamra ,MD	(RIO)
Khaled Fawzy,MD	(Zagazig)
Hisham Adel,MD	(Cairo)
Moomen Mostafa,MD	(Ain Shams)
Noureldin Abdelhamid,MD	(Azhar)

Phaco Course

1-Noureldin Abdelhamid,MD
(Azhar)

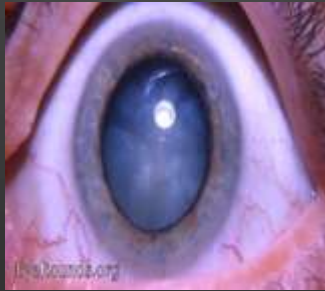
Phaco with Narrow Pupil



Basic Phaco Course

2-Khaled Fawzy,MD
(Zagazig)

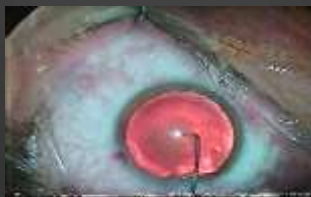White Cataract



Phaco Course

3-Amr Elsamra ,MD
(RIO)

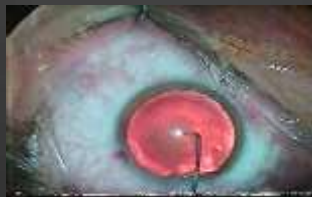Posterior polar Cataract



Phaco Course

4-Hisham Adel,MD
(Cairo)

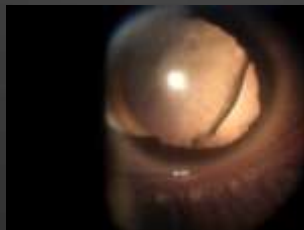
Phaco with Hard Cataract



Basic Phaco Course

5-Ahmed Ghoneim,MD
(Tanta)

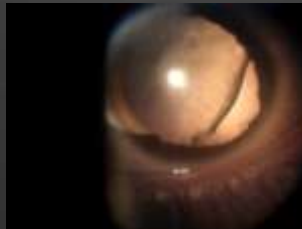
Posterior capsule Rupture



Challenging Phaco cases

6-Moomen Mostafa,MD
(Ain Shams)

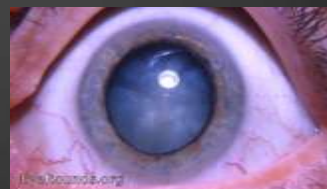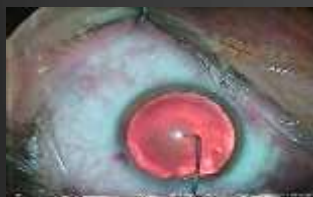Phaco with Subluxated lenses



MANAGMENT OF RUPTURE POSTERIOR CAPSULE DURING PHACO

AHMED GHONEIM,MD

Prof. of Ophthalmology
Faculty of Medicine-Tanta University
Fellow of Mainz University - Germany



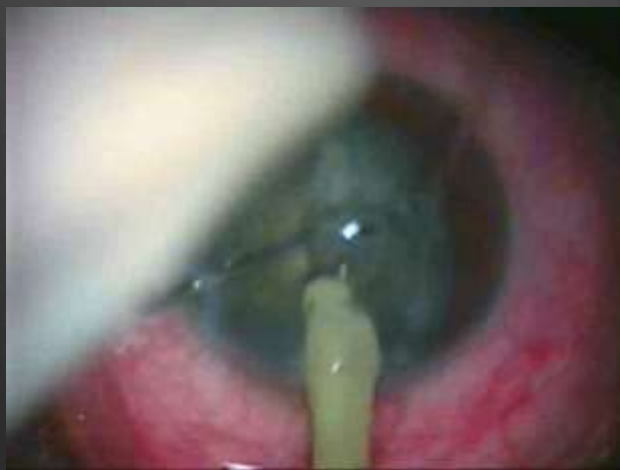Don't Forget

Rupture Posterior Capsule (Vitreous loss)

Can Occur at Any Stage During
Phaco

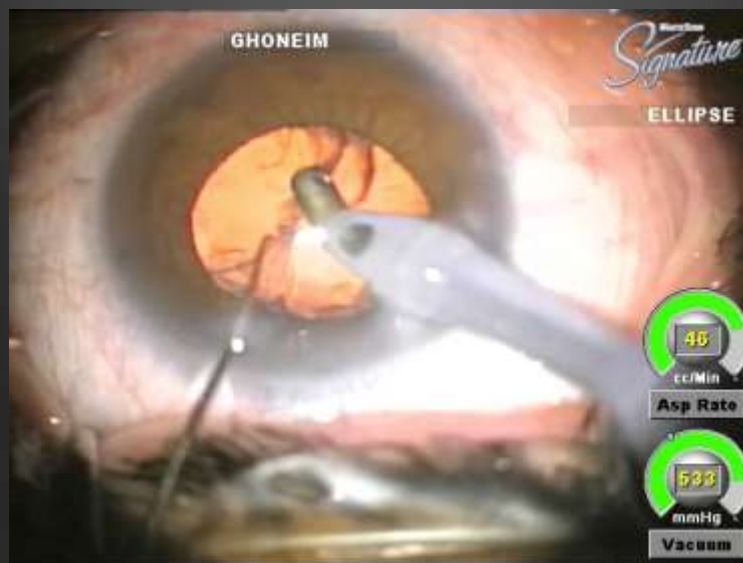Ahmed Ghoneim, MD

I NEVER FORGET

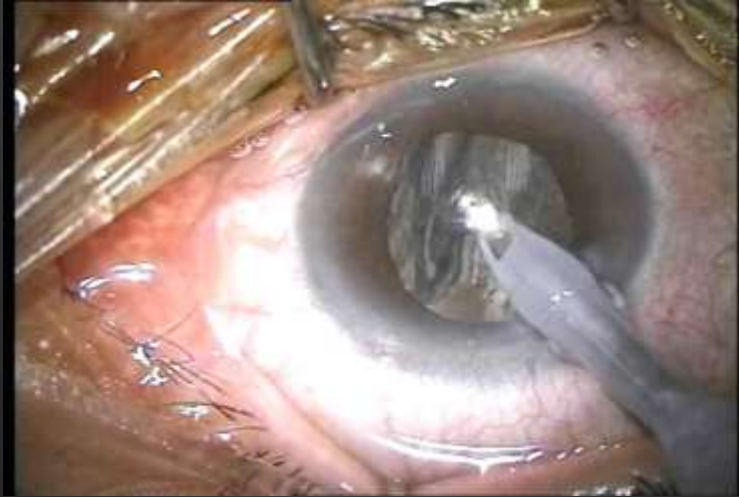


Case No.(1): Rupture with no Vit.

Post. Capsule stretch with no Vit. loss



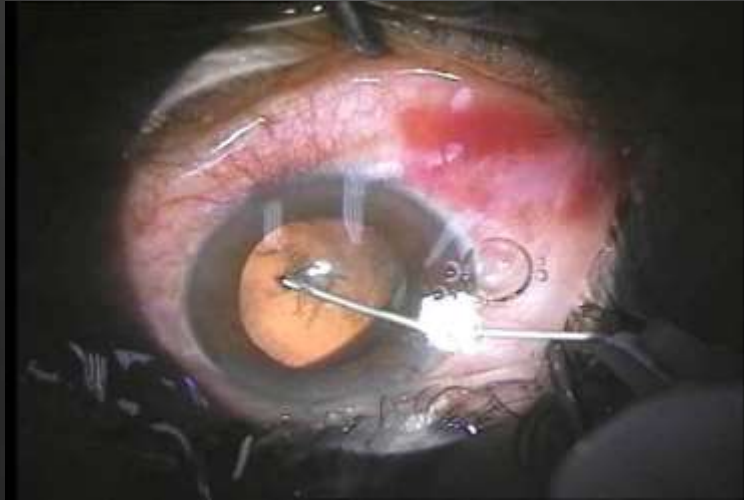
Rupture post. Capsule with no Vit. loss



First Case

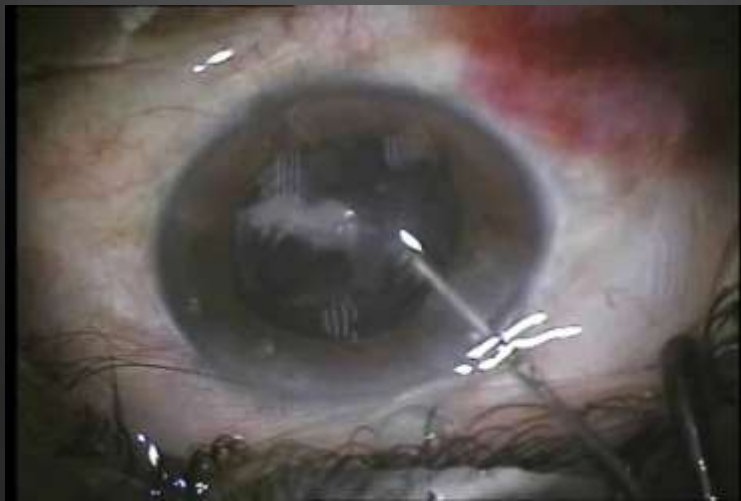
***Case No.(2):
Rupture with I/A.***

Rupture post. Capsule during I/A I



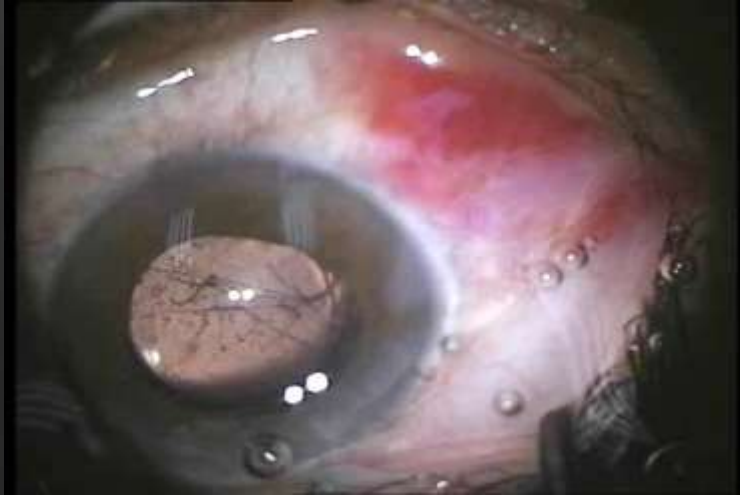Case No.2

Rupture post. Capsule during I/A II



Case No.2

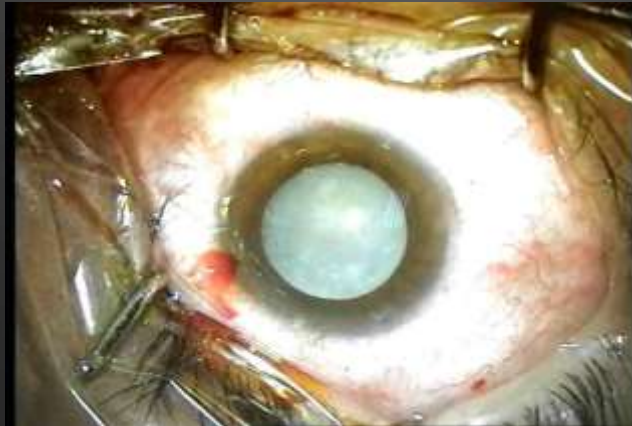Rupture post. Capsule during I/A III



Case No.2

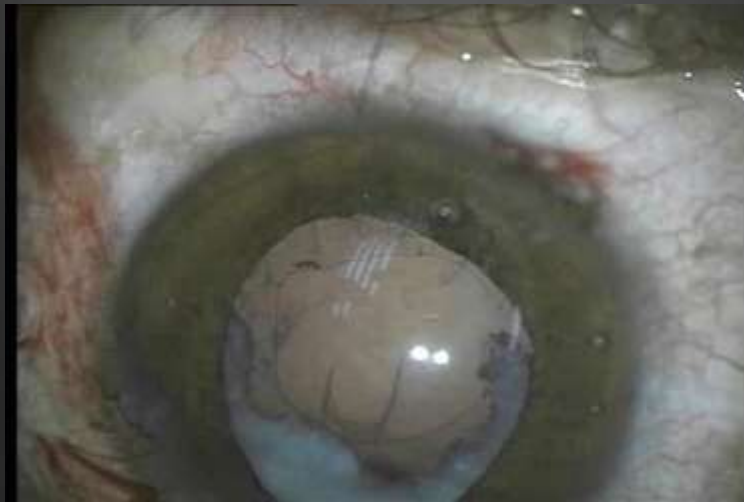***Case No.(3):
Rupture with I/A.
Hard white cataract***

Rupture post. Capsule during I/A I



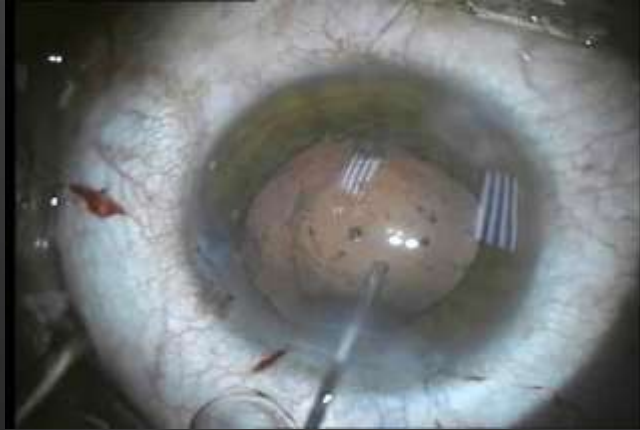
Case No.3

Rupture post. Capsule during I/A II



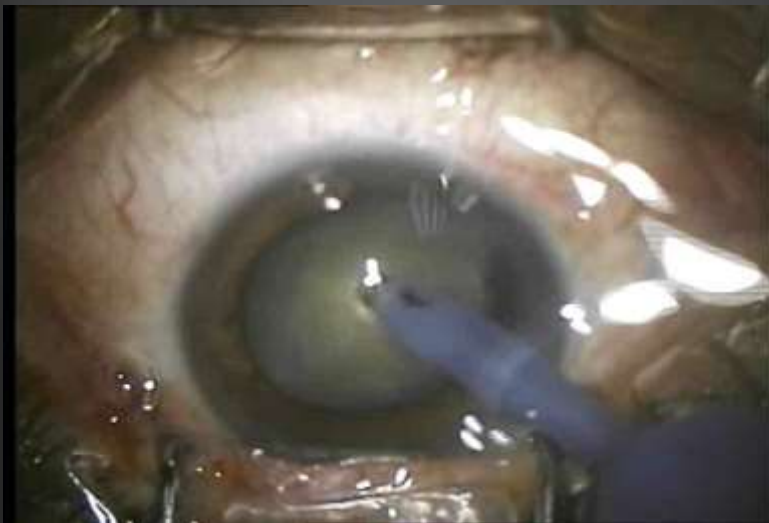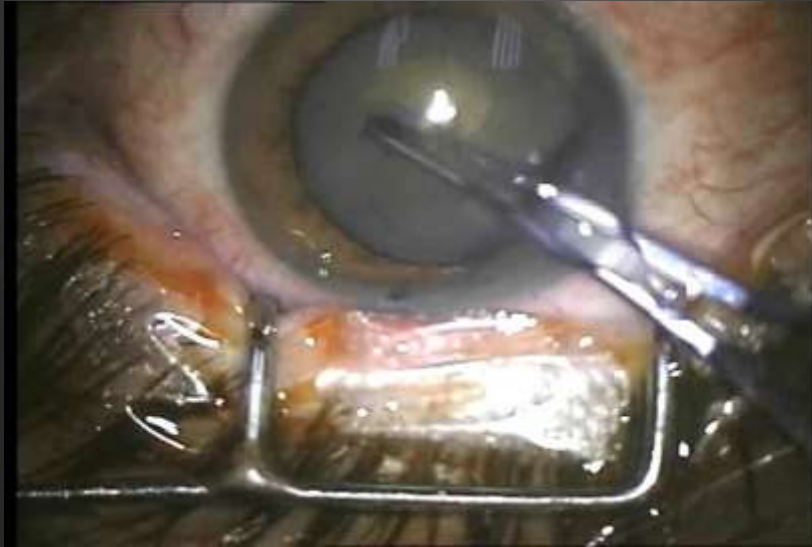Case No.3

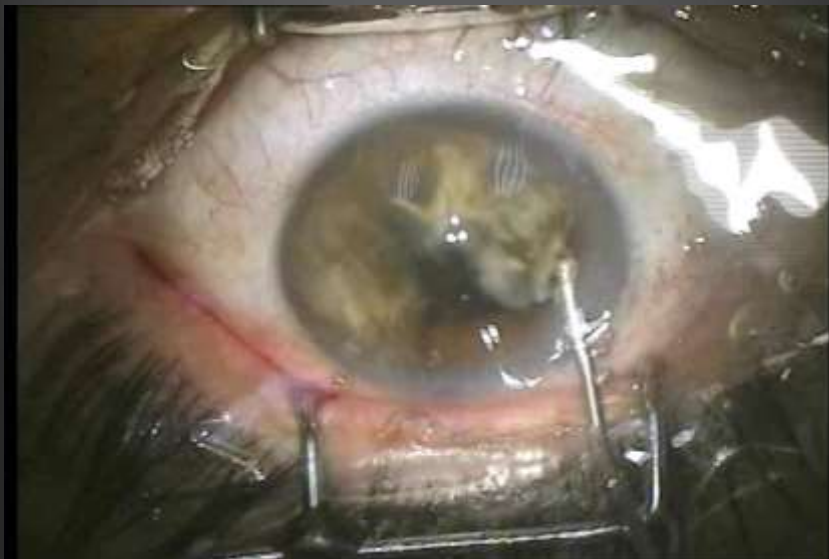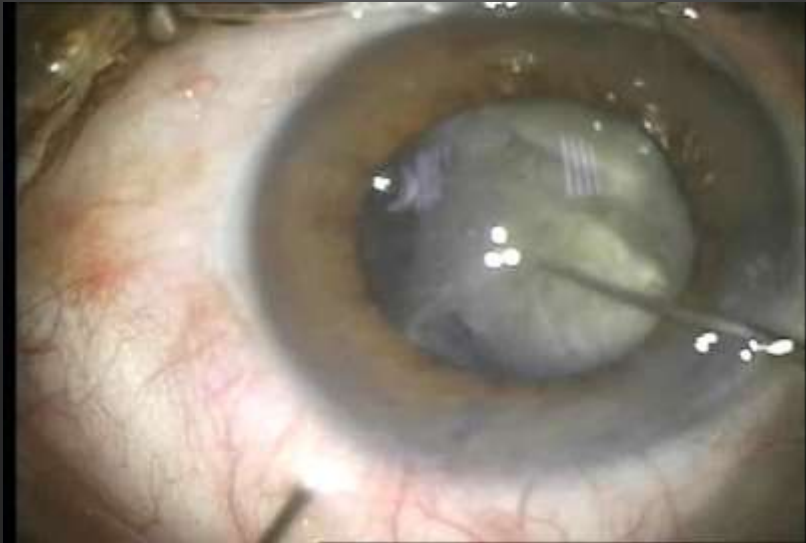Rupture post. Capsule during I/A III

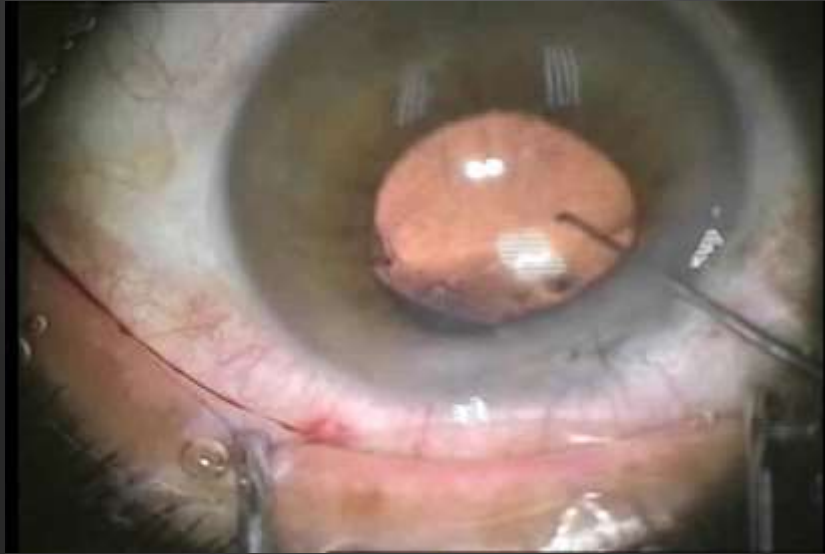


Case No.3

Case (4):
What u think
about interlocking
Force.

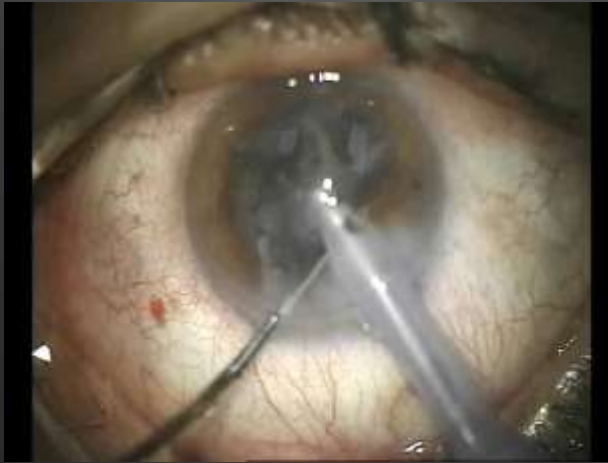





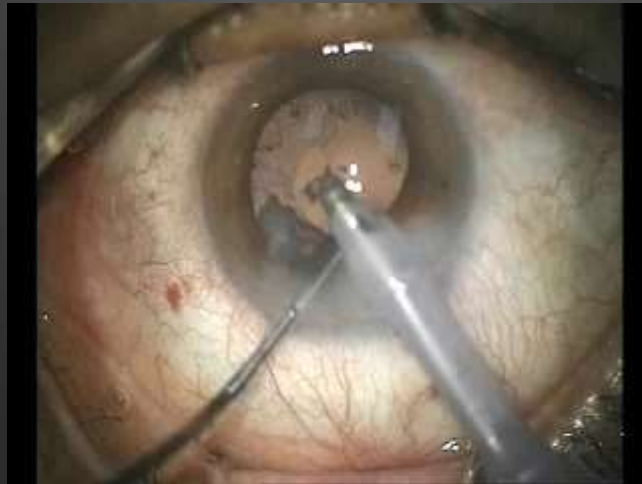***Case No.(5):
Rupture with
phaco.***

Rupture post. Capsule with phaco I



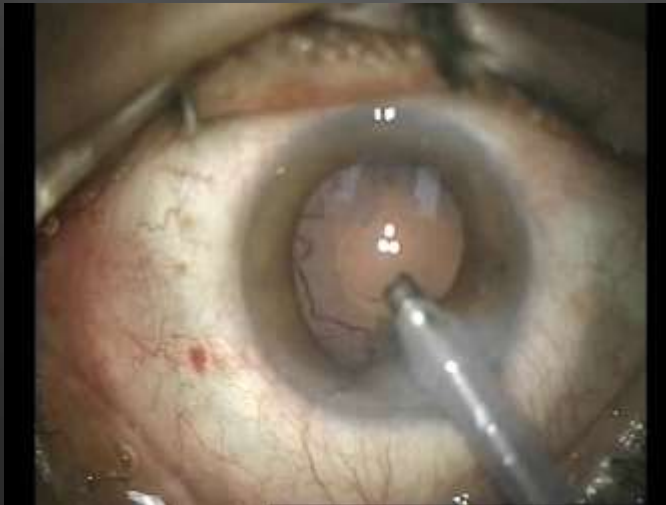Case No.5 A

Rupture post. Capsule with phaco II_{slow}



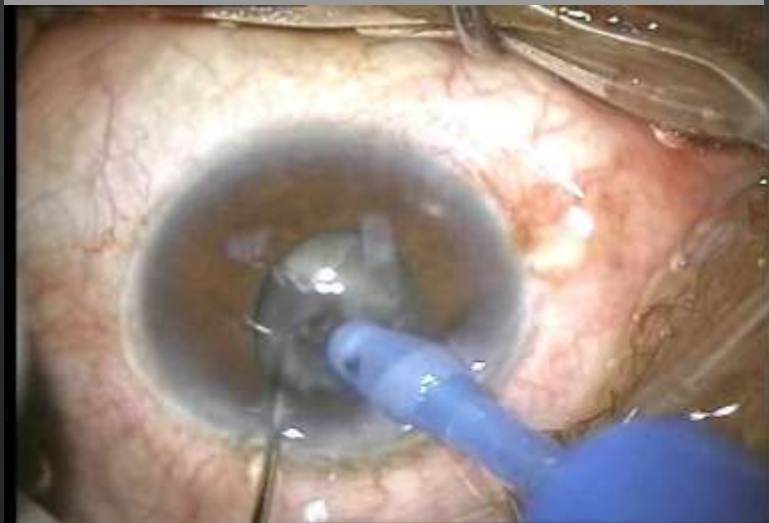Case No.5 A

Rupture post. Capsule with phaco III



Case No.5 A

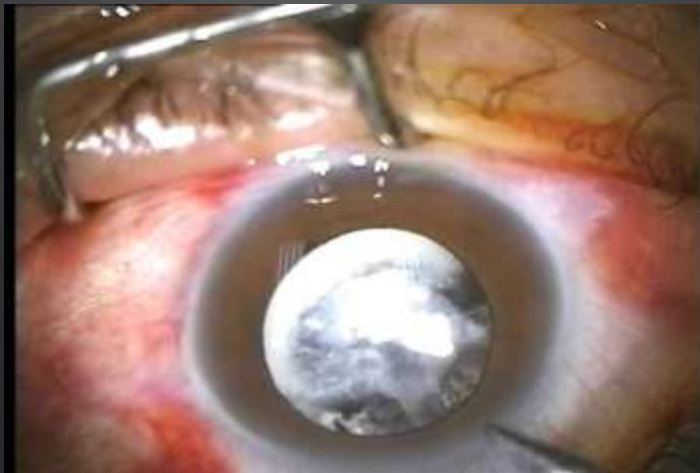Rupture post. Capsule with phaco III



Case No.5 B

Case No.(6): Membranous sheet.

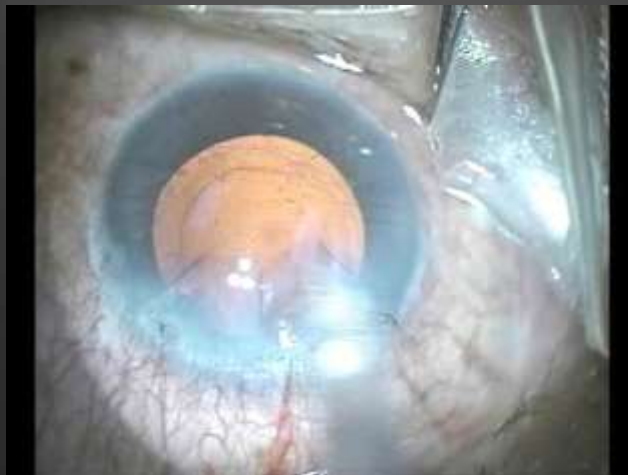Membranous ???



Case No.6

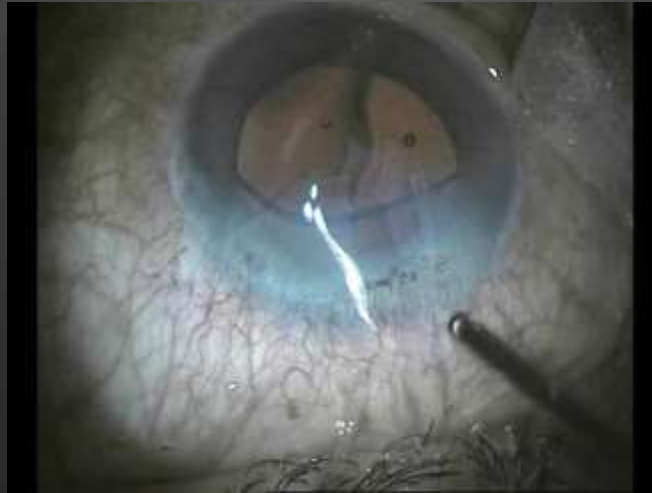Case No.(7): Vit after implantation.

Vit. after implantation I



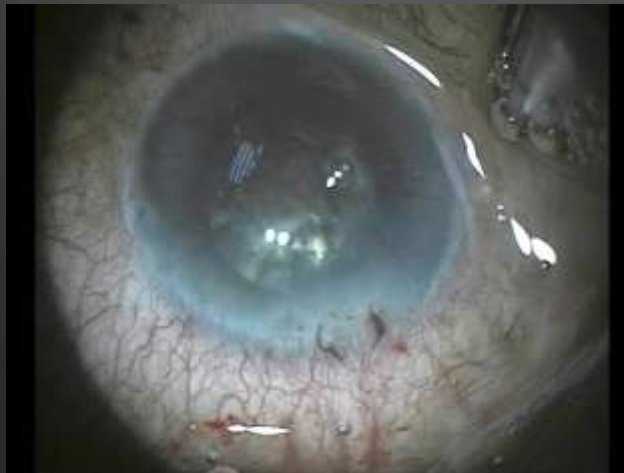Case No.7

Vit. after implantation II



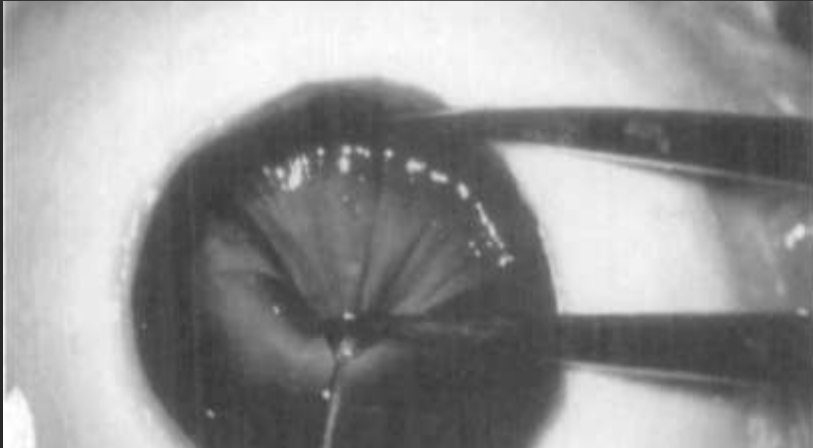
Case No.7

Vit. after implantation I



Case No.7

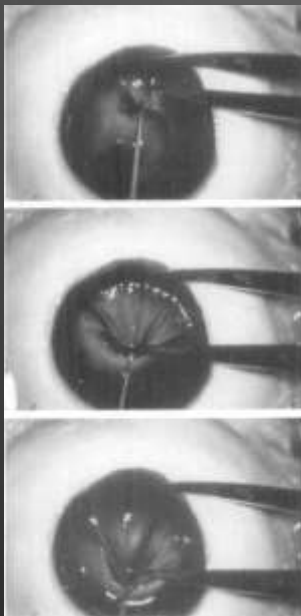
How much?? Stretching the zonule



Ahmed Ghoneim, MD

Max. zonular stretch **3.82 mm**

1.6 mm

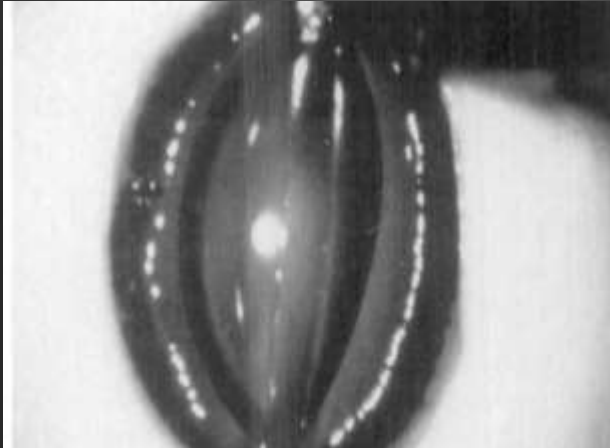

How much??

Stretching the zonule

Ahmed Ghoneim, MD

How much ?? Stretching the capsule



62%

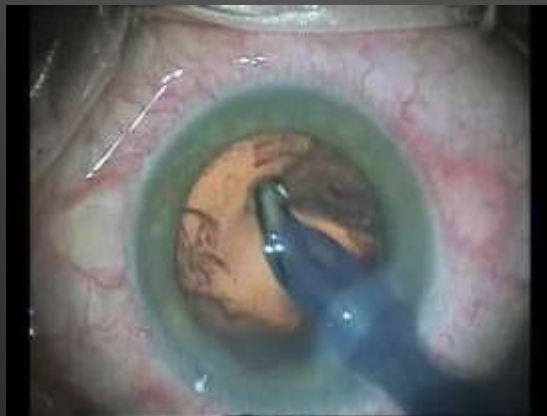6 mm = 9.72

5.5 mm = 8.91

5 mm = 8.1

Ahmed Ghoneim, MD

OK...What u think about the zonule ??



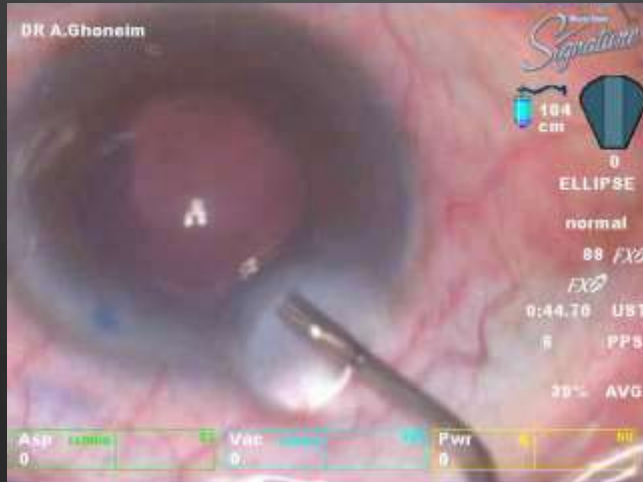Ahmed ghoneim, 2018

Case No.(8):
You finish when
you finish.

Concentrate till the end

Case No.8

You Finish when you finish



Case No.8

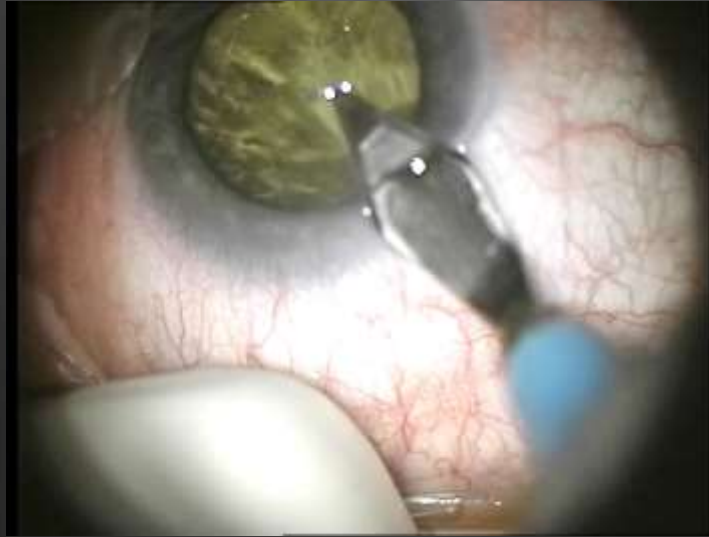**Don Not Take Early
Decisions**

Don Not Take Early Decisions



Case No. 9 :
TAC in the BAG.

TAC in the BAG

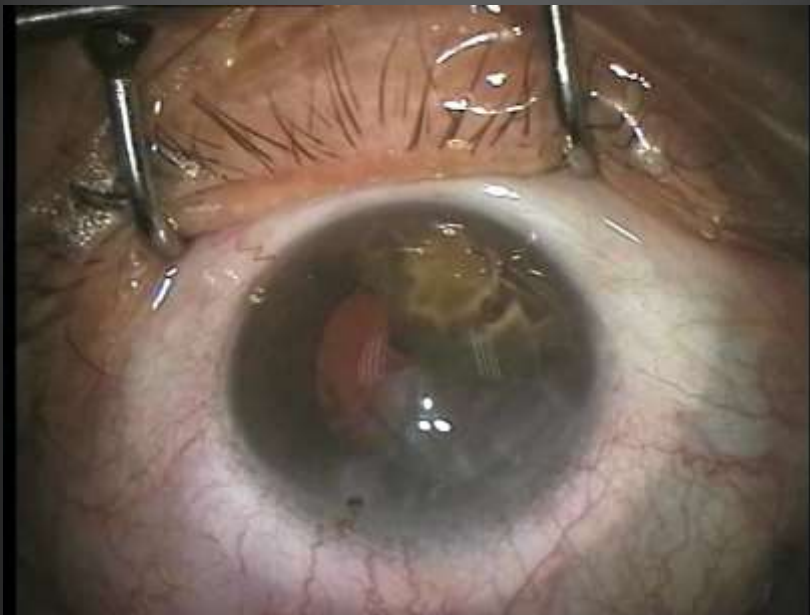
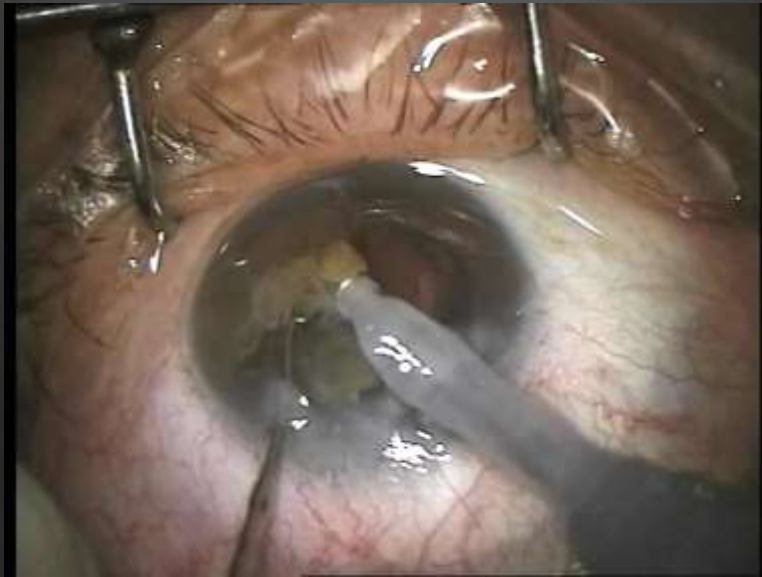
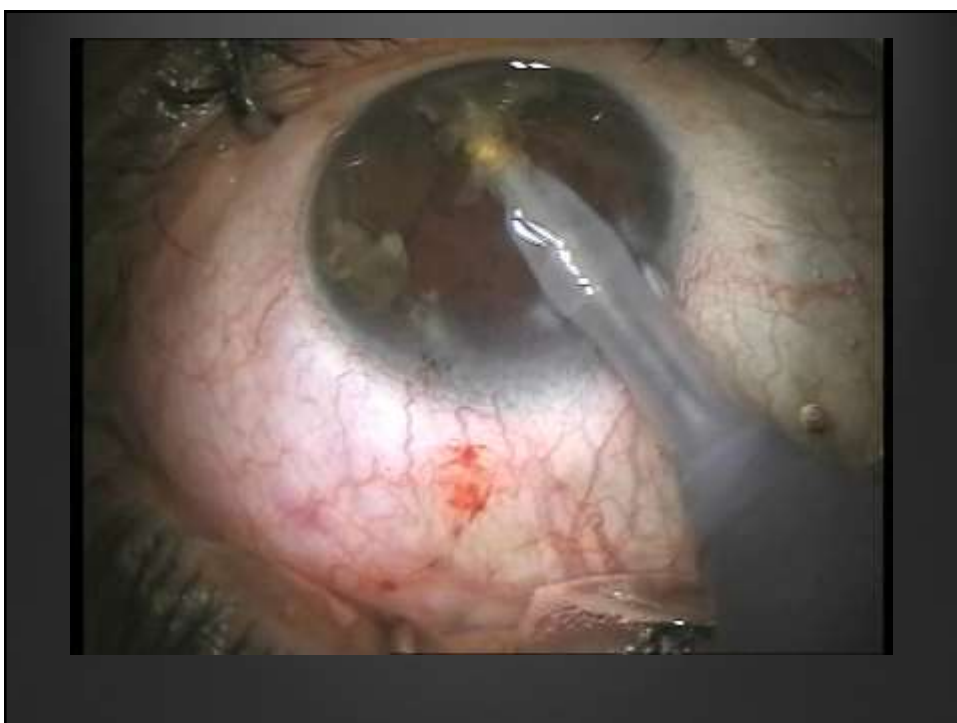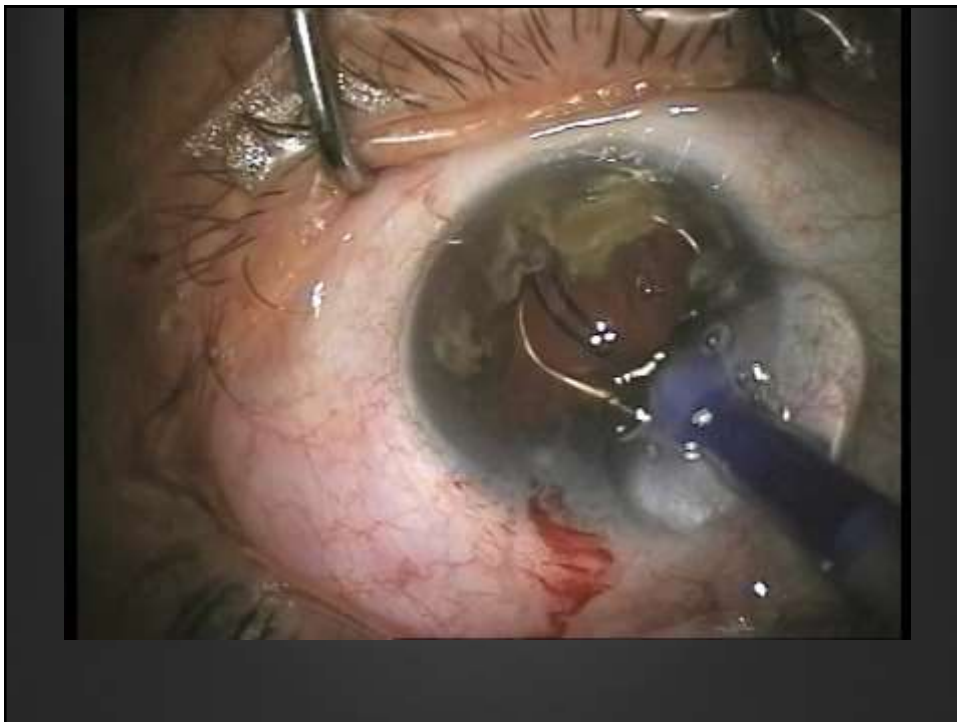
Ahmed Ghoneim, MD

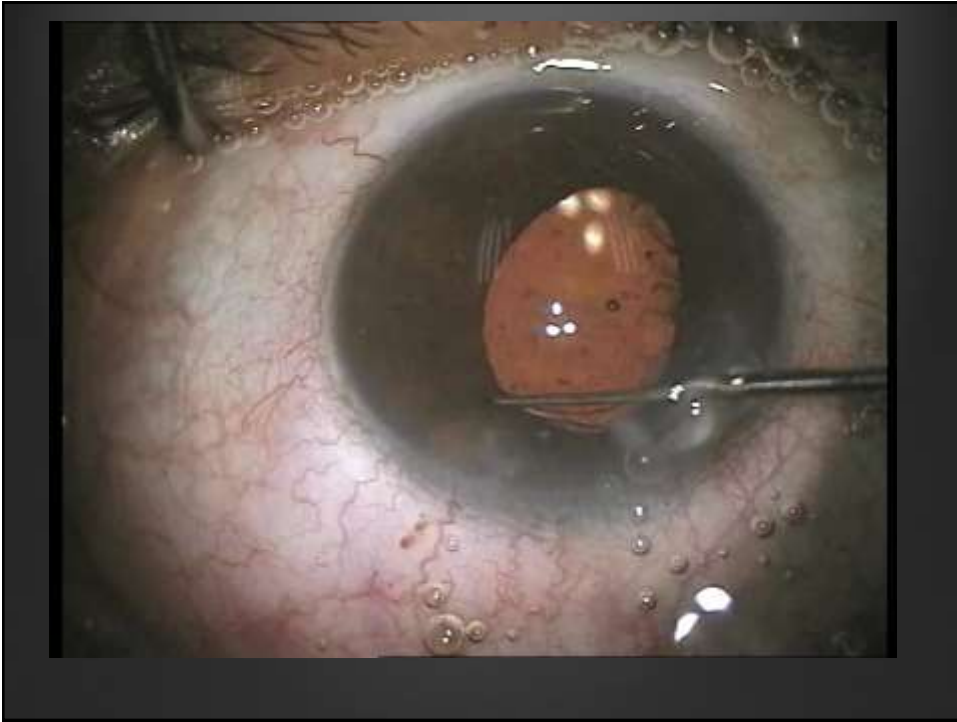
Case No 10 :

Scaffold technique.

Implant then phaco



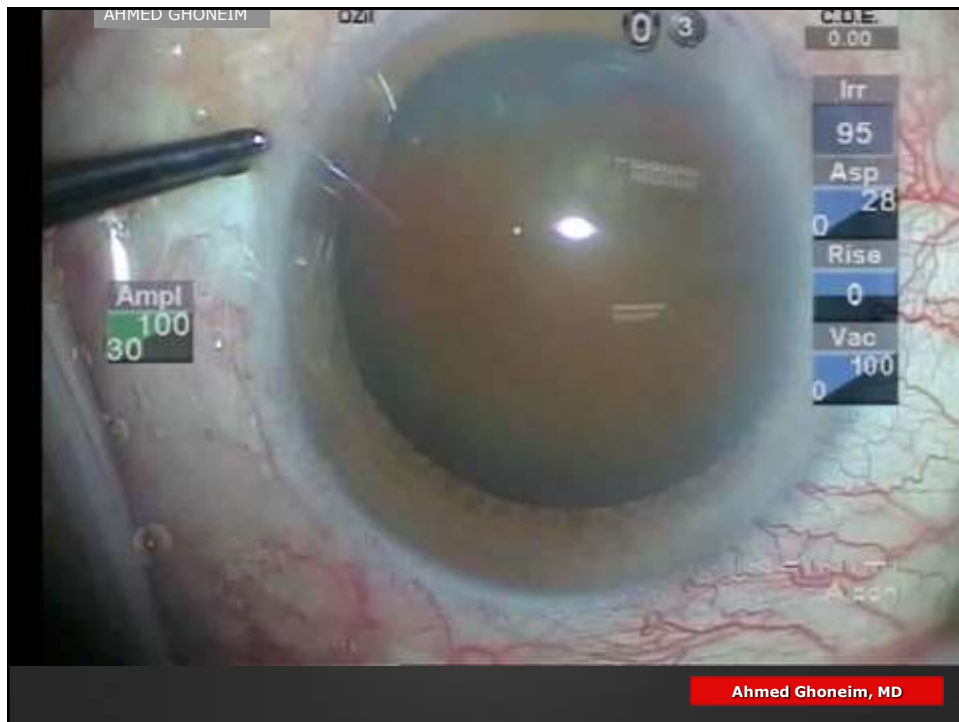



Case No 11 :

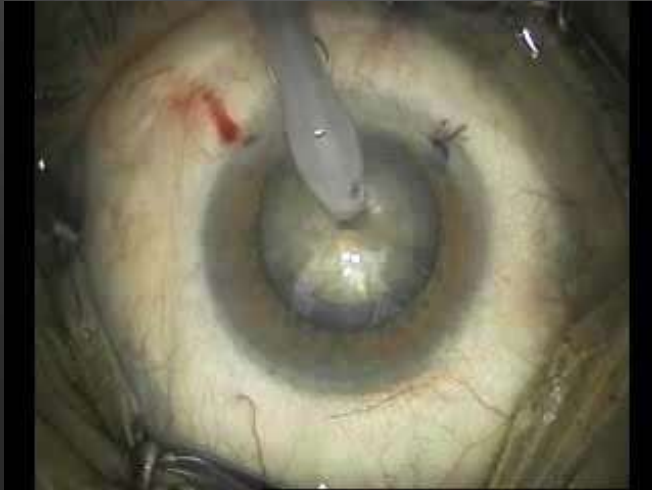Scaffold technique.

Implant then phaco

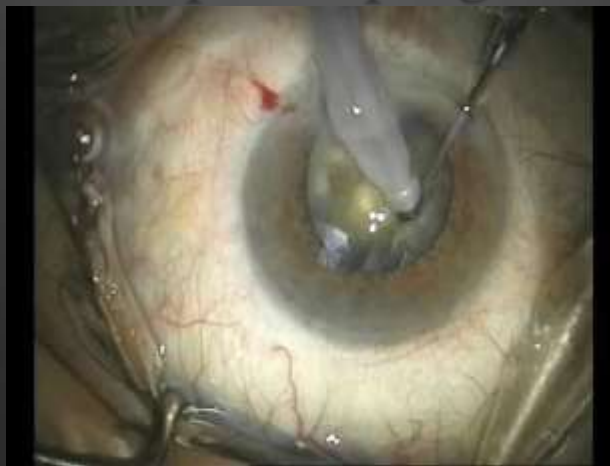

***Case: No. 12
What to do, still
need to
understand more..***

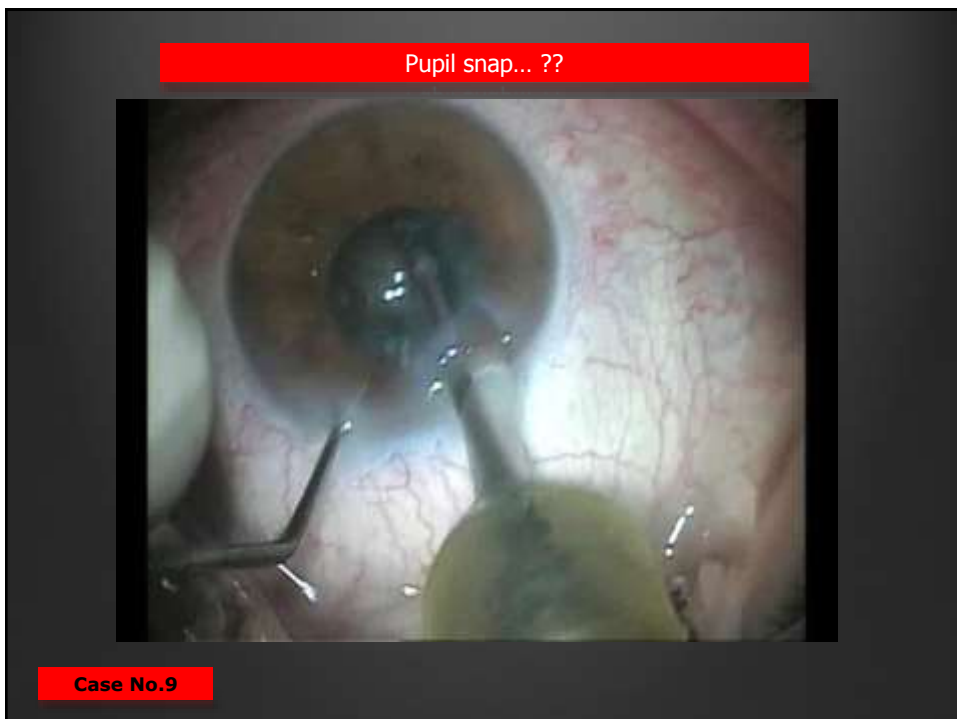
Take the Decision..



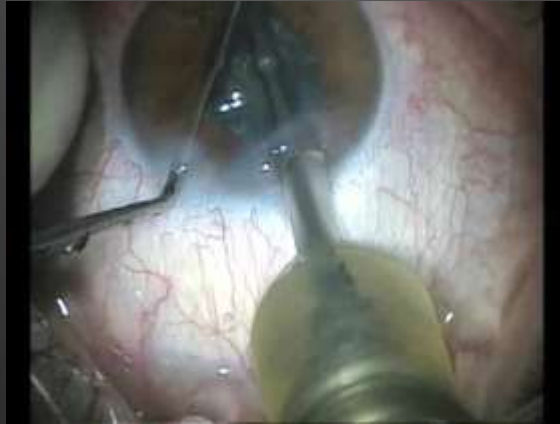Pupil snap sign



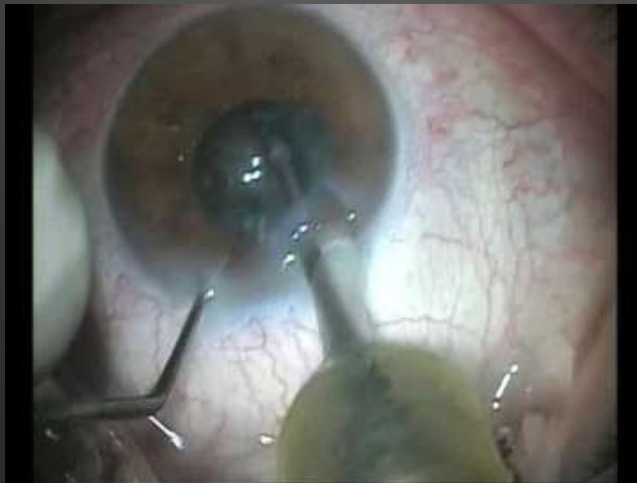***Case No.(13):
Now see it again.***



Slow motion ?? Pupil snap sign



Ahmed Ghoneim, ERC 2015

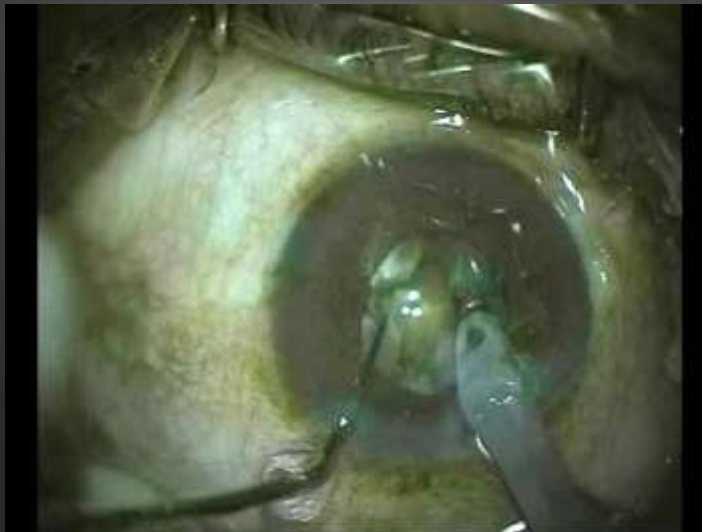

Ahmed Ghoneim, 2015

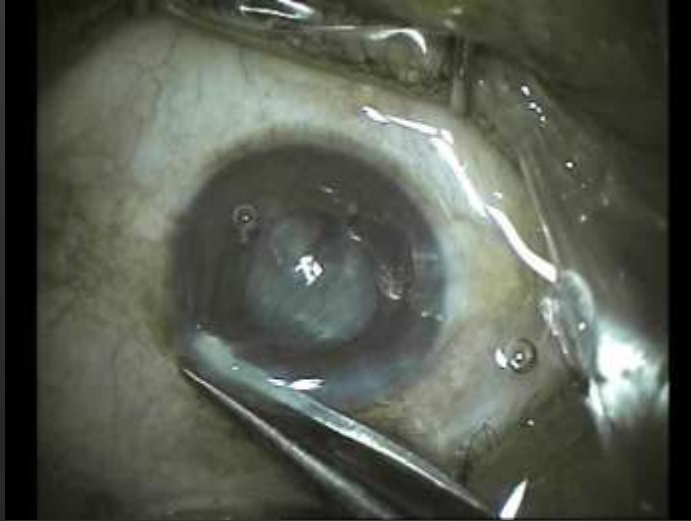Case (14):

***What u think to do
in such situation.***

Complications , how to deal ??



Complications , how to deal ??



***Case No.(15):
I hope no one face
it again ..***

You can have **big chance** but you still want to lose it.

2.26 2.36 3.10 & 3.09

MOHAMMED
MAKRANE

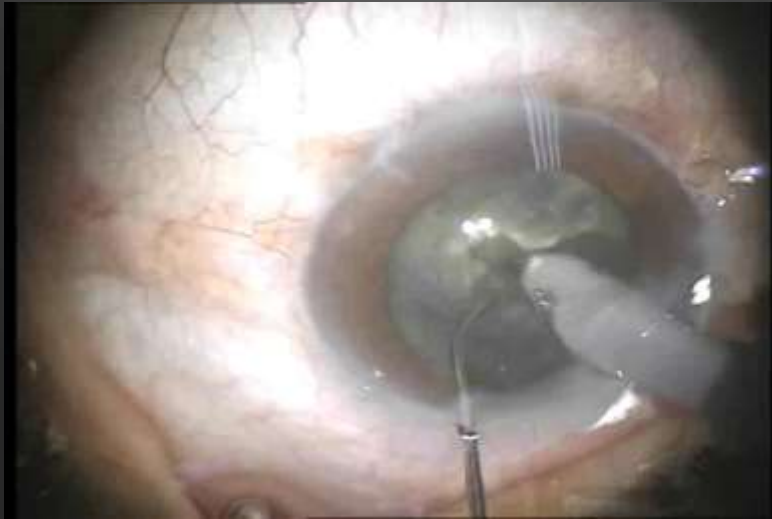
Ahmed Ghoneim, MD

Case No.(16):

***We said before
Believe it if you
see it.***

Now see it..

SEE IT ?? When u never expect.



Always look .. Not to forget ??



